

WATTS, Gordon Wayne DOB: 05/16/1966 (55 yo M) Acc No. 577279 DOS:
05/27/2021



Watts, Gordon Wayne

55 Y old Male, DOB: 05/16/1966

Account Number: 577279

2046 PLEASANT ACRE DR, PLANT CITY, FL-33566-7511

Home: 863-687-6141

Guarantor: Watts, Gordon Wayne Insurance: HCHCP

Payer ID: 59141

PCP: Robin Burns-Thigpen

Appointment Facility: NEW PLANT CITY FAMILY CARE

05/27/2021

Keion K Mark, OD

Check In: 07:58 AM EST Check Out: 09:05 AM EST

Current Medications

None

Past Medical History

PUD- due to anemia SFBH in 2017.

Left cataract surgery, managed by oph.

Surgical History

2010, left cataract surgery
Left wrist surgery 2002

Family History

Father: deceased
Mother: alive

Social History

Tobacco Use Smart Form Are you a: **never smoker.**

Literacy/Language: English only.
no Weapons in home.

Do you feel safe at home?: yes.

Sexual Hx Smart Form Had sex in the past 12 months(vaginal,oral or anal) **No**, Have you ever had an STD? **No**.

Alcohol (AUDIT-C) Screen Smart Form Did you have a drink containing alcohol in the past year? **No**, Points **0**, Interpretation **Negative**.

Tobacco use other than smoking
Other Tobacco Use **No**.

Sexual Orientation Sexual Orientation **Straight (not lesbian or gay)**.

Gender Identity Gender Identity **Male**.

Alcohol Screen (AUDIT) Smart Form Total Score:

0, Interpretation: **Alcohol Education**.

Reason for Appointment

1. Eye Exam

History of Present Illness

Optometry:

Visit type: yearly f/u. Last eye exam: 1 year ago. Ever been prescribed glasses? single vision for distance. Do you wear contacts? no.

Patient is presenting for an eye exam. Has no medical issues. Patient is aware of dilation. Patient has a mild cataract in right eye and pseudophakic in the left eye. Patient states he is taking many vitamins and cutting sugar to eliminate cataracts. Unable to perform NCT.

Vision Examination

PD

	Dist	Near
OU		
OD	30.0	
OS	30.0	

Auto Refraction

	Sph	Cyl	Axis	Add	DVA	NVA
OD	-2.25	-1.25	174			
OS	-3.00	-0.50	163			

IOP

	IOP	OD	OS	Adj OD	Adj OS	Test	Time	Category
1	15	17				Goldman	08:25 AM	

Spectacle

Presenting

	Sph	Cyl	Axis	H Prism	V Prism	Add	DVA	NVA	PH
OD	-2.00	-0.75	175			+2.25	20/25		
OS	-1.75	-1.00	115			+2.25	20/25		
OU									

Progress Note: Keion K Mark, OD 05/27/2021

WATTS, Gordon Wayne DOB: 05/16/1966 (55 yo M) Acc No. 577279 DOS:
05/27/2021

DAST-10 Drug Abuse Smart Form
Total Score: 0, Interpretation: No
problems reported.
no Children.

Allergies
N.K.D.A.

Manifest

	Sph	Cyl	Axis	H Prism	V Prism	Add	DVA	NVA	PH
OD	-2.00	-0.75	175			+2.25	20/25		
OS	-1.75	-1.00	115			+2.25	20/25		

Final

	Sph	Cyl	Axis	H Prism	V Prism	Add	DVA	NVA	PH
OD	-2.00	-0.75	175			+2.25	20/25		
OS	-1.75	-1.00	115			+2.25	20/25		
OU								20/20	

Examination

Ophthalmology/Optometry:

CONFRONTATION FIELDS FTFC OU no mg.
AFFERENT PUPILLARY DEFECT PERRLA OU.
EXTRAOCULAR MOVEMENTS: FESA OU.
EYELIDS and LASHES normal OU.
CONJUNCTIVA: normal.
CORNEA: Clear OU.
ANTERIOR CHAMBER: deep and quiet.
IRIS: WNLs.
LENS: 1+ NS OD / PCIOL OS.
DILATION: 1 gtt Tropicamide 1.0% OU / 78D superfield
Educated on blurred vision for 4-6 hrs.
FUNDI:
0.3/0.3 OD 0.3/0.3 OS,
VITREOUS: Deep and Quiet. OU
VESSELS: 2/3, Normal. OU
OPTIC NERVE: Healthy and distinct. OU
MACULA: clear and flat. OU
RETINA: intact, no signs of retinal hole, tear or detachment.
OU.

Assessments

1. Age-related nuclear cataract of eye - H25.10
2. Presbyopia OU - H52.4
3. Pseudophakia - Z96.1
4. Retinal drusen - H35.369

Treatment

1. Age-related nuclear cataract of eye

Notes:

not visually significant, monitor 12m

2. Presbyopia OU

Notes: spec rx finalized, recommended DVO. remove glasses for reading.

WATTS, Gordon Wayne DOB: 05/16/1966 (55 yo M) Acc No. 577279 DOS:
05/27/2021

3. Pseudophakia

Notes: stable, clear.

4. Retinal drusen

Notes: educated on findings, no treatment necessary. monitor 12m.

Keion Mark O.D.

Electronically signed by Keion Mark , OD on 05/27/2021 at
09:10 AM EDT

Sign off status: Pending

NEW PLANT CITY FAMILY CARE

801 E. Baker Street

340B00129100SC

Plant City, FL 33563-3652

Tel: 813-349-7600

Fax: 888-815-3533

Progress Note: Keion K Mark, OD 05/27/2021

Note generated by eClinicalWorks EMR/PM Software (www.eClinicalWorks.com)

NEW PLANT CITY FAMILY CARE

801 E. Baker Street, 340B00129100SC, Plant City, FL 33563-3652

Tel: 813-349-7600 Fax: 888-815-3533

Prepared by: Keion K Mark, OD

Keion K Mark, OD

Optometry

Watts, Gordon Wayne

2046 PLEASANT ACRE DR, PLANT CITY, FL 33566-7511

DOB: 05/16/1966 Phone: 863-687-6141

Spectacles Rx

Last year

Date: 05/27/2021

Expiry Date: 01/16/2025

Final

LAST YEAR

	Sph	Cyl	Axis	H Prism	V Prism	Add	Dist PD	Near PD
OD:	-2.00	-0.75	175			+2.25	30.5	
OS:	-1.75	-1.00	115			+2.25	30.5	

Lens Add-on's:

Notes:

⊙ Get eyeglasses + sunglasses

⊙ Ask about numbers above

⊙ Give Dr Mark grad website

⊙ Ask about Progress report

Keion Mark O.D.

DEA#: MM4579910
OPC5282

NPI: 1962841072

LIC:

Signature:

(Keion K Mark, OD)

Jun 11, 2021 15:19 PM

Watts, Gordon Wayne, M, 05/16/1966

863-688-9880

CUMULATIVE REPORT

CBC With Differential/Platelet

COLLECTION DATE	06/09/2021
Order Date	06/09/2021
Result Date	06/10/2021
Ordering Physician	Burns-Thigpen, Robin
WBC	5.2 (3.8-10.8 Thousand/uL)
RBC	4.95 (4.20-5.80 Million/uL)
Hemoglobin	15.8 (13.2-17.1 g/dL)
Hematocrit	46.3 (38.5-50.0 %)
MCV	93.5 (80.0-100.0 fL)
MCH	31.9 (27.0-33.0 pg)
MCHC	34.1 (32.0-36.0 g/dL)
RDW	11.9 (11.0-15.0 %)
Platelets	297 (140-400 Thousand/uL)
MPV	10.4 (7.5-12.5 fL)
Neutrophils (Absolute)	3193 (1500-7800 cells/uL)
Lymphs (Absolute)	1284 (850-3900 cells/uL)
Monocytes(Absolute)	406 (200-950 cells/uL)
Eos (Absolute)	244 (15-500 cells/uL)
Baso (Absolute)	73 (0-200 cells/uL)
Neutrophils	61.4 (%)
Lymphs	24.7 (%)
Monocytes	7.8 (%)
Eos	4.7 (%)
Basos	1.4 (%)

Prostatic Specific Antigen, Total (PSA)

Watts, Gordon Wayne, M, 05/16/1966

Ben Argo (Nurse)
 813-708-0717
 813-708-2017

COLLECTION DATE	06/09/2021
Order Date	06/09/2021
Result Date	06/10/2021
Ordering Physician	Burns-Thigpen, Robin
PSA, TOTAL	6.2 H (< OR = 4.0 ng/mL)

Complete Metabolic Panel (14) (CMP)

COLLECTION DATE	06/09/2021
Order Date	06/09/2021
Result Date	06/10/2021
Ordering Physician	Burns-Thigpen, Robin
Glucose, Serum	80 (65-99 mg/dL)
BUN	4 L (7-25 mg/dL)
Creatinine, Serum	1.02 (0.70-1.33 mg/dL)
BUN/Creatinine Ratio	4 L (6-22 (calc))
Sodium, Serum	139 (135-145 mmol/L)
Potassium, Serum	4.2 (3.5-5.3 mmol/L)
Chloride, Serum	102 (98-110 mmol/L)
Carbon Dioxide, Total	28 (20-32 mmol/L)
Calcium, Serum	9.6 (8.6-10.3 mg/dL)
Protein, Total, Serum	6.9 (6.1-8.1 g/dL)
Albumin, Serum	4.5 (3.6-5.1 g/dL)
Globulin, Total	2.4 (1.9-3.7 g/dL (calc))
A/G Ratio	1.9 (1.0-2.5 (calc))
Bilirubin, Total	0.4 (0.2-1.2 mg/dL)
Alkaline Phosphatase, S	71 (35-144 U/L)
AST (SGOT)	25 (10-35 U/L)
ALT (SGPT)	14 (9-46 U/L)
Glom Filtr Rate, Est	82 (> OR = 60 mL/min/1.73m2)
If African American	95 (> OR = 60 mL/min/1.73m2)

Urinalysis, Complete includes microscopic, w/rflx Culture (3020)

COLLECTION DATE	06/09/2021
Order Date	06/09/2021
Result Date	06/10/2021

Watts, Gordon Wayne, M, 05/16/1966

8304
M-F
Fr 83
New 1
Unit 4

COLLECTION DATE	06/09/2021
Ordering Physician	Burns-Thigpen, Robin
Urine-Color	YELLOW (YELLOW)
Appearance	CLEAR (CLEAR)
Specific Gravity	1:005 (1.001-1.035)
pH	7.5 (5.0-8.0)
Glucose	NEGATIVE (NEGATIVE)
Bilirubin	NEGATIVE (NEGATIVE)
Ketones	NEGATIVE (NEGATIVE)
Occult Blood	NEGATIVE (NEGATIVE)
Protein	NEGATIVE (NEGATIVE)
Nitrite	NEGATIVE (NEGATIVE)
Leuk. Esterase	NEGATIVE (NEGATIVE)
WBC	NONE SEEN (< OR = 5 /HPF)
RBC	NONE SEEN (< OR = 2 /HPF)
BACTERIA	NONE SEEN (NONE SEEN /HPF)
SQUAMOUS EPITHELIAL CELLS	NONE SEEN (< OR = 5 /HPF)
HYALINE CAST	NONE SEEN (NONE SEEN /LPF)

LIPID PANEL, Reflex DIRECT LDL

COLLECTION DATE	06/09/2021
Order Date	06/09/2021
Result Date	06/10/2021
Ordering Physician	Burns-Thigpen, Robin
CHOLESTEROL, TOTAL	153 (<200 mg/dL)
HDL CHOLESTEROL	48 (> OR = 40 mg/dL)
TRIGLYCERIDES	102 (<150 mg/dL)
LDL-CHOLESTEROL	85 (mg/dL (calc))
NON-HDL CHOLESTEROL	105 (<130 mg/dL (calc))
CHOL/HDL RATIO	3.2 (<5.0 (calc))

TSH, 3RD GENERATION W/REFLEX TO FT4

COLLECTION DATE	06/09/2021
-----------------	------------

Watts, Gordon Wayne, M, 05/16/1966

COLLECTION DATE	06/09/2021
Order Date	06/09/2021
Result Date	06/10/2021
Ordering Physician	Burns-Thigpen, Robin
TSH W/REFLEX TO FT4	2.46 (0.40-4.50 mIU/L)

Watts, Gordon Wayne, M. 05/16/1966

Gordon Watts

PROSTATE BIOPSY PATIENT INSTRUCTIONS

- ❖ **STOP ALL ASPIRIN PRODUCTS AND BLOODTHINERS ONE WEEK (SEVEN DAYS) PRIOR TO YOUR PROCEDURE**
- ❖ **TAKE THE ANTIBIOTIC(S) SUPPLIED OR GIVEN BY PRESCRIPTION. YOU WILL TAKE THEM THE DAY BEFORE THE PROCEDURE, DAY OF, AND THE DAY AFTER.**
- ❖ **THE NIGHT BEFORE THE PROCEDURE YOU WILL DRINK TWO (2) BOTTLES OF MAGNESIUM CITRATE. START AROUND 4 P.M.**
- ❖ **ONE HOUR PRIOR TO THE PROCEDURE TAKE A FLEET ENEMA (THIS CAN BE PURCHASED AT ANY PHARMACY). THIS IS TO CLEAN OUT YOUR BOWELS.**
- ❖ **YOU MAY HAVE A SMALL BREAKFAST PRIOR TO YOUR PROCEDURE.**
- ❖ **PLEASE DO NOT CALL OUR OFFICE FOR PROCEDURE RESULTS, AS WE CANNOT GIVE ANY RESULTS OVER THE TELEPHONE. WHEN RESULTS COME IN, WHICH IS TYPICALLY 7-10 BUSINESS DAYS FOLLOWING YOUR PROCEDURE, WE WILL CALL YOU TO SCHEDULE AN APPOINTMENT WITH THE DOCTOR.**
- ❖ **IF YOU HAVE ANY QUESTIONS PLEASE CALL OUR OFFICE AT (813)719-6920.**
- ❖ **\$60 FOR NUMBING OF THE PROSTATE IS CHARGED THE DAY OF PROCEDURE (INSURANCE DOES NOT PAY FOR NUMBING).**

APPOINTMENT DATE:

Tuesday
July 27, 2021

APPOINTMENT TIME:

10:45 A.M.

Start. 1/20

Go to Pharmacy Monday

Not with Ciprotax

Monday

9:45 AM Tuesday 2 night bt

Assistant said to do it once a night before of night 1 night 64

M-R	830 AM 430 P
Fri	900 AM 300 P
New 1 Lunch	

Gordon Watts

Dr. Nancy
August 9 2021
Hospital

Aug 31, 2021 29450

RTE: FEAPS 013-356-0218 SEQ: FABY

DIANON SYSTEMS

Department of Uropathology

Connecticut Lic. #: CL-0356

FAABY08 DIAGNOSTIC REPORT

**FLORIDA UROLOGY PARTNERS LAB
 6913 WEBB ROAD**

TAMPA, FL 33616

Accession No. PA1203925	Chart No. WATGOR0002	Sex M	D.O.B. 05/16/1966 55 Yrs	Page 1 of 5
Patient Name WATTS, GORDON				Collected 07/27/21
Requesting Physician AFRIDA, SALIM K, MD				Received 07/31/21
Referring Physician BURNS-THIGPEN, ROBIN				Reported 08/03/21

Clinical Data

PATHOLOGY CONSULTATION

■ SPECIMEN 10: Prostate CNB, Left Lateral Apex

DIAGNOSIS:

PROSTATIC ADENOCARCINOMA. GLEASON'S SCORE 7 (GRADES 3 + 4) NOTED IN 1 OUT OF 1 SUBMITTED PROSTATE CORE SEGMENTS. APPROXIMATELY 20% OF SUBMITTED TISSUE INVOLVED... GLEASON GRADE 4 COMPRISES 10% OF THE TUMOR. SEE COMMENT.

Comments:

Negative staining with both high molecular weight cytokeratin and p63 in suspicious glands favors the diagnosis of adenocarcinoma of the prostate. In addition, the diagnosis of prostatic adenocarcinoma is supported by the positive staining for racemase (P404S), which is preferentially expressed in prostate cancer. All controls show appropriate immunoreactivity.

■ SPECIMEN 5: Prostate CNB, Left Mid

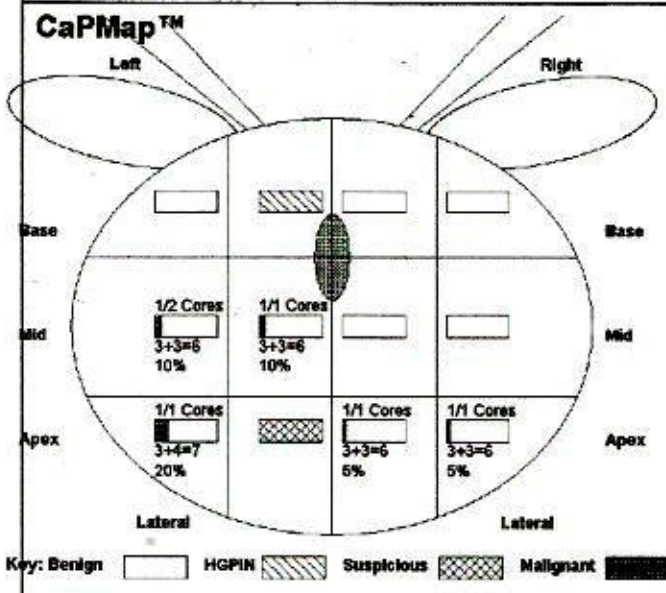
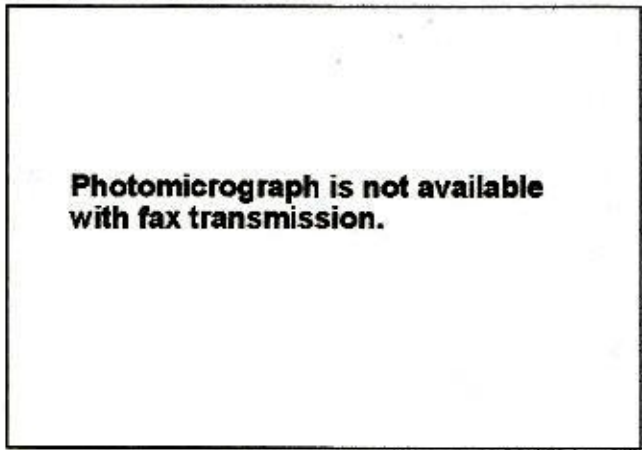
DIAGNOSIS:

PROSTATIC ADENOCARCINOMA. GLEASON'S SCORE 6 (GRADES 3 + 3) NOTED IN 1 OUT OF 1 SUBMITTED PROSTATE CORE SEGMENTS. APPROXIMATELY 10% OF SUBMITTED TISSUE INVOLVED... SEE COMMENT.

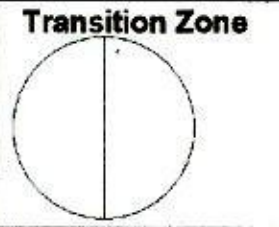
Comments:

Negative staining with both high molecular weight cytokeratin and p63 in suspicious glands favors the diagnosis of adenocarcinoma of the prostate. In addition, the diagnosis of prostatic adenocarcinoma is supported by the positive staining for racemase (P404S), which is preferentially expressed in prostate cancer. All controls show appropriate immunoreactivity.

PHOTOMICROGRAPH



Other



CONTINUED ON NEXT PAGE

DIANON SYSTEMS

Department of Uropathology

Connecticut Lic. #: CL-0356

FAABY08

DIAGNOSTIC REPORT

Accession No.	Chart No.	Sex	D.O.B.	Page
PA1203925	WATGOR0002	M	05/16/1966 55 Yrs	2 of 5
Patient Name				Collected
WATTS, GORDON				07/27/21
Requesting Physician				Received
AFRIDA, SALIM K, MD				07/31/21
Referring Physician				Reported
BURNS-THIGPEN, ROBIN				08/03/21

PATHOLOGY CONSULTATION (Continued)

■ SPECIMEN 11: Prostate CNB, Left Lateral Mid

DIAGNOSIS:

PROSTATIC ADENOCARCINOMA. GLEASON'S SCORE 6 (GRADES 3 + 3) NOTED IN 1 OUT OF 2 SUBMITTED PROSTATE CORE SEGMENTS. APPROXIMATELY 10% OF SUBMITTED TISSUE INVOLVED...

■ SPECIMEN 1: Prostate CNB, Right Apex

DIAGNOSIS:

PROSTATIC ADENOCARCINOMA. GLEASON'S SCORE 6 (GRADES 3 + 3) NOTED IN 1 OUT OF 1 SUBMITTED PROSTATE CORE SEGMENTS. APPROXIMATELY 5% OF SUBMITTED TISSUE INVOLVED... SEE COMMENT.

Comments:

Negative staining with both high molecular weight cytokeratin and p63 in suspicious glands favors the diagnosis of adenocarcinoma of the prostate. In addition, the diagnosis of prostatic adenocarcinoma is supported by the positive staining for racemase (P404S), which is preferentially expressed in prostate cancer. All controls show appropriate immunoreactivity.

■ SPECIMEN 7: Prostate CNB, Right Lateral Apex

DIAGNOSIS:

PROSTATIC ADENOCARCINOMA. GLEASON'S SCORE 6 (GRADES 3 + 3) NOTED IN 1 OUT OF 1 SUBMITTED PROSTATE CORE SEGMENTS. APPROXIMATELY 5% OF SUBMITTED TISSUE INVOLVED... SEE COMMENT.

Comments:

Negative staining with both high molecular weight cytokeratin and p63 in suspicious glands favors the diagnosis of adenocarcinoma of the prostate. In addition, the diagnosis of prostatic adenocarcinoma is supported by the positive staining for racemase (P404S), which is preferentially expressed in prostate cancer. All controls show appropriate immunoreactivity.

■ SPECIMEN 4: Prostate CNB, Left Apex

DIAGNOSIS:

SMALL FOCUS OF ATYPICAL GLANDS, SUSPICIOUS FOR LOW GRADE ADENOCARCINOMA. SEE COMMENT.

Comments:

Although these findings are atypical and suspicious for adenocarcinoma, there is insufficient cytologic and/or architectural atypia to establish a definitive diagnosis.

■ SPECIMEN 8: Prostate CNB, Left Base

DIAGNOSIS:

PROSTATIC INTRAEPITHELIAL NEOPLASIA (PIN), HIGH GRADE.

CONTINUED ON NEXT PAGE

DIANON SYSTEMS

Department of Uropathology

Connecticut Lic. #: CL-0356

FAABY08

DIAGNOSTIC REPORT

Accession No. PA1203925	Chart No. WATGOR0000	Sex M	D.O.B. 05/16/1966 55 Yrs	Page 3 of 5
Patient Name WATTS, GORDON				Collected 07/27/21
Requesting Physician AFRIDA, SALIM K, MD				Received 07/31/21
Referring Physician BURNS-THIGPEN, ROBIN				Reported 08/03/21

PATHOLOGY CONSULTATION (Continued)

SPECIMEN 2: Prostate CNB, Right Mid

DIAGNOSIS:

BENIGN PROSTATE TISSUE. NO EVIDENCE OF MALIGNANCY.

SPECIMEN 3: Prostate CNB, Right Base

DIAGNOSIS:

BENIGN PROSTATE TISSUE. NO EVIDENCE OF MALIGNANCY.

SPECIMEN 8: Prostate CNB, Right Lateral Mid

DIAGNOSIS:

BENIGN PROSTATE TISSUE. NO EVIDENCE OF MALIGNANCY.

SPECIMEN 9: Prostate CNB, Right Lateral Base

DIAGNOSIS:

BENIGN PROSTATE TISSUE. NO EVIDENCE OF MALIGNANCY.

SPECIMEN 12: Prostate CNB, Left Lateral Base

DIAGNOSIS:

BENIGN PROSTATE TISSUE. SEE COMMENT.

Comments:

Although a focus of glands in this specimen exhibited some features warranting further investigation, positive staining with both high molecular weight cytokeratin and p63 is evidence that the glands are benign. In addition, negative staining with racemase (p504s) further supports the benign nature of the glands in question. This case has been reviewed at the daily intradepartmental conference. All controls show appropriate immunoreactivity.

CONTINUED ON NEXT PAGE

DIANON SYSTEMS

Department of Uropathology

Connecticut Lic. #: CL-0356

FAABY08

DIAGNOSTIC REPORT

Accession No. PA1203925	Chart No. WATGOR0000	Sex M	D.O.B. 05/16/1966 55 Yrs	Page 4 of 5
Patient Name WATTS, GORDON				Collected 07/27/21
Requesting Physician AFRIDA, SALIM K, MD				Received 07/31/21
Referring Physician BURNS-THIGPEN, ROBIN				Reported 08/03/21

PATHOLOGY CONSULTATION (Continued)

GROSS DESCRIPTION


Container/Location	Received	Pieces	Measurement	Description	Ink	Submitted
(10)Left Lateral Apex	in prostate fixative		16 mm	pale tissue	Not inked	In 1 cassette
(5)Left Mid	in prostate fixative		21 mm	pale tissue	Not inked	In 1 cassette
(11)Left Lateral Mid	in prostate fixative		17 to 18 mm	pale tissue	Not inked	In 1 cassette
(1)Right Apex	in prostate fixative		17 mm	pale tissue	Not inked	In 1 cassette
(7)Right Lateral Apex	in prostate fixative		9 mm	pale tissue	Not inked	In 1 cassette
(4)Left Apex	in prostate fixative		17 mm	pale tissue	Not inked	In 1 cassette
(6)Left Base	in prostate fixative		15 mm	pale tissue	Not inked	In 1 cassette
(2)Right Mid	in prostate fixative		17 mm	pale tissue	Not inked	In 1 cassette
(3)Right Base	in prostate fixative		15 mm	pale tissue	Not inked	In 1 cassette
(8)Right Lateral Mid	in prostate fixative		18 mm	pale tissue	Not inked	In 1 cassette
(9)Right Lateral Base	in prostate fixative		12 mm	pale tissue	Not inked	In 1 cassette
(12)Left Lateral Base	in prostate fixative		11 mm	pale tissue	Not inked	In 1 cassette

Totally Submitted

COMMENTS

This case was reviewed at the daily intradepartmental conference.

The length and number of cores reported may differ from that noted during the procedure or on receipt by the laboratory due to tissue shrinkage and/or fragmentation during processing.



Savvas E. Mendrinos, M.D.

PERFORMING LABS

Performed by DIANON Systems, 1 Forest Parkway, Shelton CT 06484, Jonathan L. Klein, M.D., Medical Director, 1-800-328-2666

CONTINUED ON NEXT PAGE

DIANON SYSTEMS

Department of Uropathology

Connecticut Lic. #: CL-0366

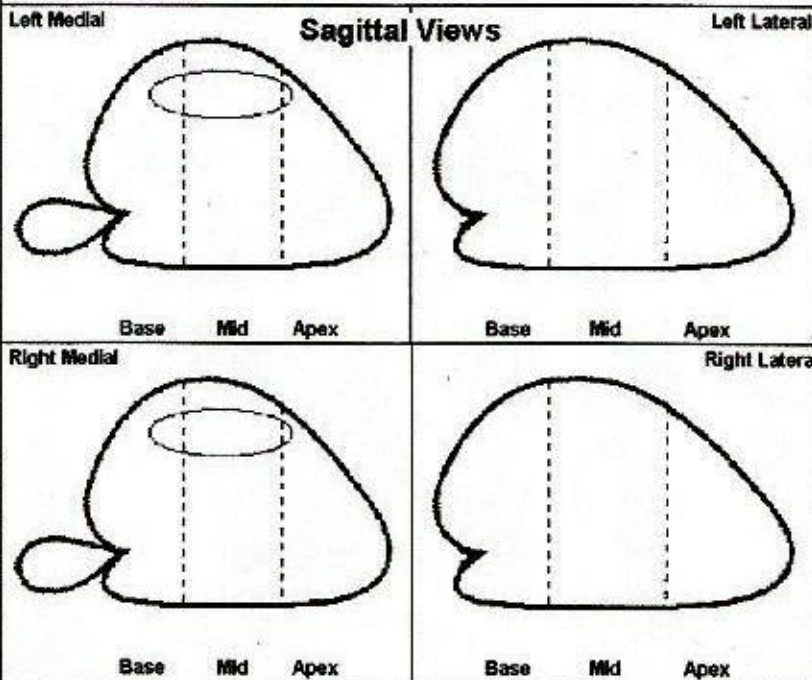
FAABY08

DIAGNOSTIC REPORT

Accession No. PA1203925	Chart No. WATGOR0002	Sex M	D.O.B. 05/16/1966 55 Yrs	Page 5 of 5
Patient Name WATTS, GORDON				Collected 07/27/21
Requesting Physician AFRIDA, SALIM K, MD				Received 07/31/21
Referring Physician BURNS-THIGPEN, ROBIN				Reported 08/03/21

BIOPSY SUMMARY

Location	Diagnosis	Core Length(mm)	Tumor Length(mm)	% Tumor	Tumor Position From Inked Margin
Left Lateral Apex (Core 1/1)	3+4=7	10	2.0	20%	Not Inked
Left Mid (Core 1/1)	3+3=6	10	1.0	10%	Not Inked
Left Lateral Mid (Core 1/2)	3+3=6	10	2.0	20%	Not Inked
Right Apex (Core 1/1)	3+3=6	10	0.5	5%	Not Inked
Right Lateral Apex (Core 1/1)	3+3=6	10	0.5	5%	Not Inked



DNA Histogram

207 North Plant Ave.
Plant City, FL 33567

Salim K. Afridi, M.D.

Ph: 813-719-6920
Fax: 813-719-6398

Date: 8/20/2021
Gordon Watts

Patient Name: _____

Date of Birth: 5/16/1966

Diagnosis: Prostate CA

Dr. Signature: 

Return Office Visit: _____ Days _____ Weeks _____ Months

Do Diagnostic Studies: STAT

Before next visit 3-7 days

*Get
PSA exam
on 12/13/21 or earlier.*

Investigation Sheet

in 4 months from

Lab (Circle): Urine
Urine (Multistick & Microscope)
Urine C&S Cath/Void
Urine Cytology x 3
Other: _____

Blood work: Fasting Yes No
CBC (CPT-85025)
Hemogram (CPT-85021)
PT, PTT, Bleeding Time, Platelets
PTH C-Terminal
RPR, ESR, PSA + FREE PSA,
Creatinine, Bun, Uric Acid,
Testosterone Total Free
FSH, Prolactin, TSH

Overnight/10 Hours
Profiles: BMP (CPT-80049), CMP (CPT-80054)
Lipid Profile (CPT-80061)
Hepatic Function Panel A (CPT-80058)
Other: _____
Semen Analysis Complete Post Vasectomy
Stone for Crystallo Graphic Analysis
Sperm or Prostatic Fluid Culture & Sensitivity
Of any amount of Bacteria
Other: _____

Lab test to be done at Dr. _____

X-RAYS:
Abdomen (1) View, KUB
KUB + 20 minutes Post Injec.
VCU, Cystogram
IVP W/Allergy Protocol (W/O) (W)
Limited IVP
Retrograde Urethrogram

Nuclear Medicine:
Bone Scan "Whole Body"
Renal Scan/Renal Function-
R&L Kidney/Renogram - Diuretic

Pelvis (W/O) (W) Contrast
Retro peritoneum
Ultrasound:
Abdomen, (GB) (Liver) (Pancreas)
Bladder

Allergies: _____

MRI:
MRI-Kidney/Retroperitoneum
Cat Scan:
Abdomen (WO) (W) Contrast
Kidney (WO) (W) Contrast

Kidneys
Testicular (W) Color Doppler
Other Imaging/Diagnostic Test
No Oral Contrast/Hematuria Protocol
EKG
Other: _____

X-Ray Facilities: Please Send X-Rays to Office with Patient

IT IS THE PATIENT'S RESPONSIBILITY TO OBTAIN ANY REQUIRED REFERRALS FROM THEIR PRIMARY CARE PHYSICIAN OR THROUGH THEIR INSURANCE COMPANY PRIOR TO THE LABORATORY TESTS OR X-RAYS NEEDED, CHECK WITH YOUR INSURANCE COMPANY FOR THE REQUIREMENTS OF WHICH FACILITY THEY APPROVE FOR YOUR TESTING BY INITIALING BELOW, I HEREBY UNDERSTAND AND ACKNOWLEDGE THE ABOVE STATEMENTS.

Patient's Initials: _____