

## PET CT SKULL BASE TO MID THIGH

 Not yet reviewed by care team.

### Results New

#### Universal Viewer Tower

Show images for PET CT SKULL BASE TO MID THIGH

#### Study Result

##### *Narrative & Impression*

PET CT SKULL BASE TO MID THIGH

CLINICAL INDICATION:

Male, 58 years old. Malignant neoplasm of prostate (HC CODE)

TECHNIQUE:

PET images of vertex of the skull to the mid thigh with arms above the head were performed 53 minutes post dose.

Low dose non contrast CT was performed for attenuation correction and localization.

RADIOPHARMACEUTICAL:

6.4 mCi of GA 68 gozetotide IV.

COMPARISON:

The outside FDG PET/CT scan performed on 10/2/2023 is not available for comparison but there is no dictated report.

FINDINGS:

Head and Neck: There is physiological P SMA expression in the head and neck region of symmetrical radiotracer uptake by the salivary glands. The parotid glands have a max SUV of 18.8.

There is no evidence of P SMA avid adenopathy in the right or left side of the head and neck region..

Chest: Review of the bone window shows no evidence of P SMA avid soft tissue nodules opacities or infiltrates in the right or the left lung parenchyma. Both the right and left lung pleura are unremarkable.

There is no P SMA avid adenopathy in the axillary, internal mammary, mediastinal or hilar lymph nodes.

Abdomen and Pelvis: There is physiologic P SMA expression in the spleen, pancreas and adrenal glands. The right and left liver lobe have uniform P SMA expression with a max SUV of 5.8.

In the abdomen there is no evidence of P SMA avid mesenteric or retroperitoneal adenopathy including the right and left periaortic region. This is unchanged since the prior PET/CT scan, 10/02/2023 which have no hypermetabolic adenopathy.

Physiologic P SMA excretion in the GI and GU tract. The abdominal aortic blood pool activity has a max SUV of 2.1.

In the pelvis the prostate gland is intact. The posterior left side of the prostate gland has a P SMA avid focus extending from the base to the apex measuring 2.2 x 1.4 cm with a max SUV of 7.2. This lesion was also FDG avid on the prior PET/CT scan,

10/02/2023, (max SUV of 7.0, 0.9 x 1.4 cm). The remaining portions of the prostate gland show more uniform and less intense P SMA expression.

Outside the prostate gland there is no evidence of P SMA avid iliac or inguinal adenopathy in the right or left side of the pelvis. This is unchanged since the prior FDG PET/CT scan, 10/2/2023.

Skeleton: There is physiologic P SMA expression in the visualized skeleton.

IMPRESSION:

Posterior left side of the prostate gland extending from the base to the apex has a PSMA avid lesion with a mi-PSMA

expression score\* of 2. It corresponds to the hypermetabolic lesion seen on the outside PET/CT scan, 10/2/2023, and meets the diagnostic

criteria for primary prostate malignancy.

There is no evidence of P SMA avid soft tissue metastasis in the pelvis, abdomen or above the diaphragm including the thorax and head and neck region.

The osseous structures are unremarkable.

\*Prostate Cancer Molecular Imaging Standardized Evaluation (PROMISE): Proposed miTNM Classification for the Interpretation of PSMA-Ligand PET/CT

Matthias Eiber, Ken Herrmann, Jeremie Calais, Boris Hadaschik, Frederik L. Giesel, Markus Hartenbach, Thomas Hope, Robert Reiter, Tobias Maurer, Wolfgang A. Weber and Wolfgang P. Fendler

Journal of Nuclear Medicine March 2018, 59 (3) 469-478; DOI: <https://doi.org/10.2967/jnumed.117.198119>

Workstation: 109-1246



# IMAGING

3350 Bell Shoals Road  
Brandon, FL 33511-7637

## \*\*\* FINAL IMAGING REPORT \*\*\*

**Patient Name: Watts, Gordon**  
**Date of Exam: 07/12/2024 1:37 PM**

**Procedures Performed: PET CT SKULL BASE TO MID THIGH**

**Accession #: E09265692**

**Order #: 313226596**

**Patient Class: Outpatient**

**Patient Name: Watts, Gordon**

**DOB: 5/16/1966**

**Ordering Prov: Akm Mosharraf Hossain**  
**Prov Addr: 1601 W TIMBERLANE DR**  
**STE 100**  
**PLANT CITY FL 33566**

**Age: 58 y.o. Sex: Male**

**MRN: 101222864**

**Account:**

**Diagnosis:**

**Reason For Exam:**

**Financial Class: N/A**

**DSN Session ID:**

**DSN Appropriateness Score:**

**DSN Support Source:**

**CDSM Identifier:**

**DSN Adherence Identification:**

**DSN Date/Time:**

**DSN Hardship Exception:**

**DSN Comment:**

**Associated CPT Codes: 78815**

**PET CT SKULL BASE TO MID THIGH**

**CLINICAL INDICATION:**

Male, 58 years old. Malignant neoplasm of prostate (HC CODE)

**TECHNIQUE:**

PET images of vertex of the skull to the mid thigh with arms above the head were performed 53 minutes post dose. Low dose non contrast CT was performed for attenuation correction and localization.

**RADIOPHARMACEUTICAL:**

6.4 mCi of GA 68 gozetotide IV.

**COMPARISON:**

The outside FDG PET/CT scan performed on 10/2/2023 is not available for comparison but there is no dictated report.

**FINDINGS:**

Head and Neck: There is physiological P SMA expression in the head and neck region of symmetrical radiotracer uptake by the salivary glands. The parotid glands have a max SUV of 18.8.

There is no evidence of P SMA avid adenopathy in the right or left side of the head and neck region..

Chest: Review of the bone window shows no evidence of P SMA avid soft

tissue nodules opacities or infiltrates in the right or the left lung parenchyma. Both the right and left lung pleura are unremarkable. There is no P SMA avid adenopathy in the axillary, internal mammary, mediastinal or hilar lymph nodes.

Abdomen and Pelvis: There is physiologic P SMA expression in the spleen, pancreas and adrenal glands. The right and left liver lobe have uniform P SMA expression with a max SUV of 5.8.

In the abdomen there is no evidence of P SMA avid mesenteric or retroperitoneal adenopathy including the right and left periaortic region. This is unchanged since the prior PET/CT scan, 10/02/2023 which have no hypermetabolic adenopathy.

Physiologic P SMA excretion in the GI and GU tract. The abdominal aortic blood pool activity has a max SUV of 2.1.

In the pelvis the prostate gland is intact. The posterior left side of the prostate gland has a P SMA avid focus extending from the base to the apex measuring 2.2 x 1.4 cm with a max SUV of 7.2. This lesion was also FDG avid on the prior PET/CT scan,

10/02/2023, (max SUV of 7.0, 0.9 x 1.4 cm). The remaining portions of the prostate gland show more uniform and less intense P SMA expression.

Outside the prostate gland there is no evidence of P SMA avid iliac or inguinal adenopathy in the right or left side of the pelvis. This is unchanged since the prior FDG PET/CT scan, 10/2/2023.

Skeleton: There is physiologic P SMA expression in the visualized skeleton.

#### IMPRESSION:

Posterior left side of the prostate gland extending from the base to the apex has a PSMA avid lesion with a mi-PSMA expression score\* of 2. It corresponds to the hypermetabolic lesion seen on the outside PET/CT scan, 10/2/2023, and meets the diagnostic criteria for primary prostate malignancy.

There is no evidence of P SMA avid soft tissue metastasis in the pelvis, abdomen or above the diaphragm including the thorax and head and neck region.

The osseous structures are unremarkable.

\*Prostate Cancer Molecular Imaging Standardized Evaluation (PROMISE): Proposed miTNM Classification for the Interpretation of PSMA-Ligand PET/CT  
Matthias Eiber, Ken Herrmann, Jeremie Calais, Boris Hadaschik, Frederik L. Giesel, Markus Hartenbach, Thomas Hope, Robert Reiter, Tobias Maurer, Wolfgang A. Weber and Wolfgang P. Fendler  
Journal of Nuclear Medicine March 2018, 59 (3) 469-478; DOI: <https://doi.org/10.2967/jnumed.117.198119>  
Workstation: 109-1246

Electronically Signed By: Luke Bolek, MD on 7/17/2024 1:24 PM

CC'd Recipients:

Series 3: CT AC 50 FOV (CT)

ID: 101222864

Reviewer

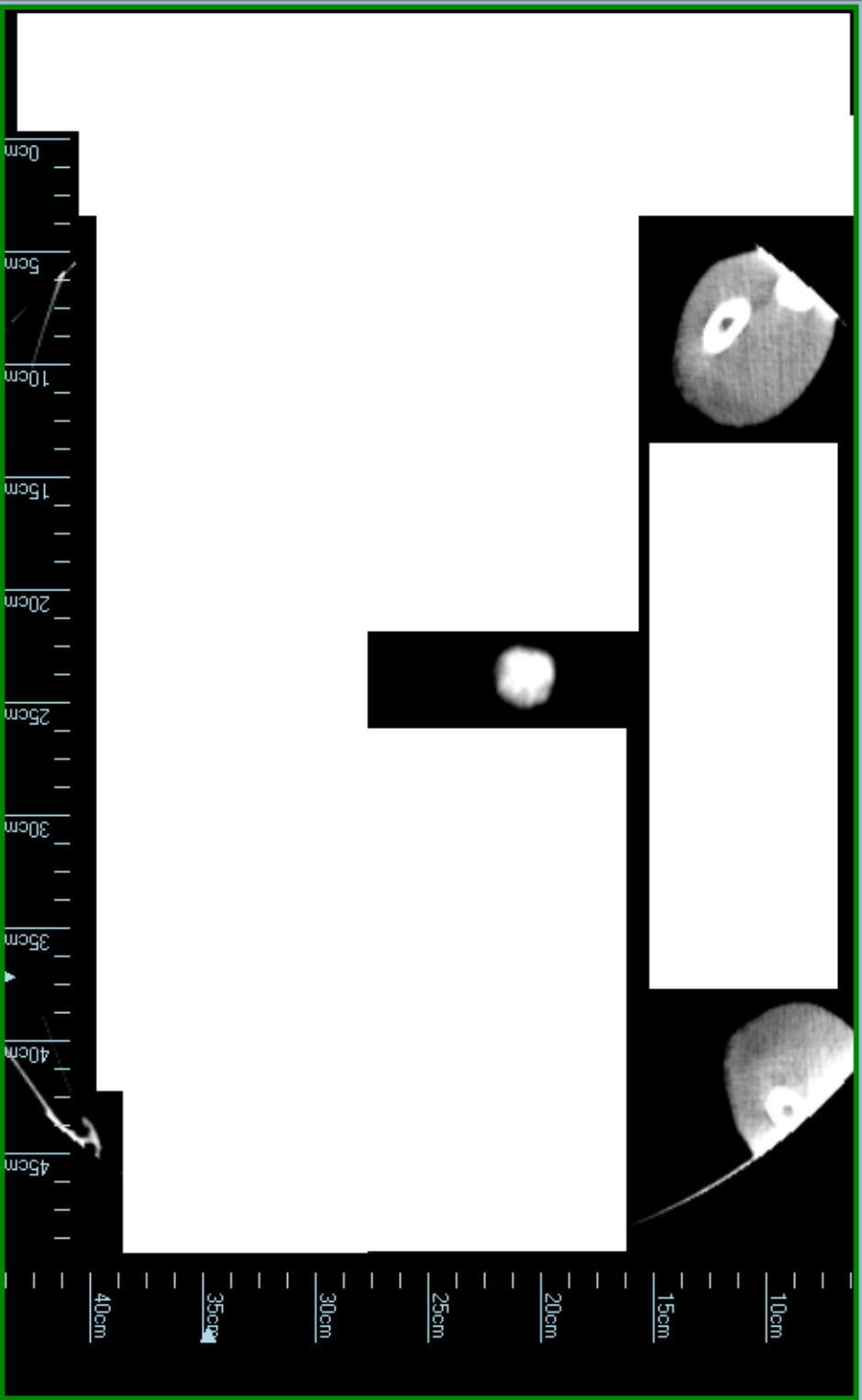
Inst: BLM Tower Radiology

File Edit View Study Series Image Help



Study Explorer GORDON WATTS - CT - PET CT SKULL BASE TO MID THIGH - 7/12/2024

Series 3: CT AC 50 FOV (CT)



Series 3: CT AC 50 FOV (CT)

ID: 101222864

A

Inst: BLM Tower Radiology

DOB: \*\*\*\*\*

Patient: \*\*\*\*\*


File Edit View Study Series Image Help

016.0 [016.0 actual] fps

Study Explorer

GORDON WATTS - CT - PET CT SKULL BASE TO MID THIGH - 7/12/2024

Series 3: CT AC 50 FOV (CT)



Study Explorer: **GORDON WATTS - CT - PET CT SKULL BASE TO MID THIGH - 7/12/2024**

Series 3: CT AC 50 FOV (CT)

ID: 101222864 Inst: BLM Tower Radiology

DOB: 5/16/1966 Sex: M Ref MD: AKM MOSHARRAF HOSSAIN

W: 255 - L: 127

Img # 1

016.0 (016.0 actual) fps

Study Explorer: **GORDON WATTS - CT - PET CT SKULL BASE TO MID THIGH - 7/12/2024**

Series 13: WB 3D MAC (PT)

ID: 101222864 Inst: BLM Tower Radiology

DOB: 5/16/1966 Sex: M Ref MD: AKM MOSHARRAF HOSSAIN

W: 255 - L: 127

Img # 1

016.0 (016.0 actual) fps

Study Explorer: **GORDON WATTS - CT - PET CT SKULL BASE TO MID THIGH - 7/12/2024**

Series 12: WB 3D AC (PT)

ID: 101222864 Inst: BLM Tower Radiology

DOB: 5/16/1966 Sex: M Ref MD: AKM MOSHARRAF HOSSAIN

W: 255 - L: 127

Img # 1

016.0 (016.0 actual) fps

Study Explorer: **GORDON WATTS - CT - PET CT SKULL BASE TO MID THIGH - 7/12/2024**

Series 999: Dose Report (CT)

ID: 101222864 Inst: BLM Tower Radiology

DOB: 5/16/1966 Sex: M Ref MD: AKM MOSHARRAF HOSSAIN

W: 1024 - L: 512

A# E09265692

SE: 999 IM: 1

KV: 111

mAs: 111

DFOV: mm

TILT: mm

Soma Corporation

Series 1200: FUSED AXIAL (OT)

ID: 101222864 Inst: BLM Tower Radiology

DOB: 5/16/1966 Sex: M Ref MD: AKM MOSHARRAF HOSSAIN

W: 255 - L: 127

Img # 1

016.0 (016.0 actual) fps

DFOV 52.0 cm

50 X PET

Series 1201: FUSED COR (OT)

ID: 101222864 Inst: BLM Tower Radiology

DOB: 5/16/1966 Sex: M Ref MD: AKM MOSHARRAF HOSSAIN

W: 255 - L: 127

Img # 1

016.0 (016.0 actual) fps

DFOV 99.8 cm

50 X PET

Series 1200: FUSED AXIAL (OT)

ID: 101222864 Inst: BLM Tower Radiology

DOB: 5/16/1966 Sex: M Ref MD: AKM MOSHARRAF HOSSAIN

W: 255 - L: 127

Img # 1

016.0 (016.0 actual) fps

DFOV 52.0 cm

50 X PET

ID	Series	Type	Scan Range (mm)	CUVoi (mGy)	DLP (mGy-cm)	Ref MD	Acq Trm	Inst
101222864	1	Scout	-	-	-	AKM MOSHARRAF HOSSAIN	H: 59 AM	BLM Tower Radiology
101222864	2	Helical	120,000-1991.480	1.77	177.48 Pat	AKM MOSHARRAF HOSSAIN	H: 59 AM	BLM Tower Radiology
				Total Exam DLP:	177.48			

ID: 101222864  
DOB: 5/16/1966 Sex: M  
W: 1024 - L: -512  
A#: E09265692  
SE: 999 IM: 1

Patient Name: WATTS GORDON  
Accession Number: E09265692  
Patient ID: 101222864  
Exam Description: PET CT SKULL BASE TO MID THIGH

Exam no: 10330  
Jul 12 2024  
Discovery IQ

Inst: BLM Tower Radiology  
Ref MD: AKM MOSHARRAF HOSSAIN  
Acq Tm: 11:59 AM  
Pat Pos: HFS

### Dose Report

Series	Type	Scan Range (mm)	CTDIvol (mGy)	DLP (mGy-cm)	Phantom cm
1	Scout	-	-	-	-
2	Helical	120.000-1991.480	1.77	177.48	Body 32
Total Exam DLP:			177.48		

1/1

KV:  
mA:  
DFOV:  
mm  
TILT:

Some Corporation

ALG:  
CONT:  
ZOOM: 100.00%  
512x512

File Edit View Study Series Image Help

Study Explorer: GORDON WATTS - CT - PET CT SKULL BASE TO MID THIGH - 7/12/2024

ID: 101222864  
 Series 3: CT AC 50FOV (CT)

File Edit View Study Series Image Help

Study Explorer: GORDON WATTS - CT - PET CT SKULL BASE TO MID THIGH - 7/12/2024

ID: 101222864  
 Series 999: Dose Report (CT)

Inst: BLM Tower Radiology  
 Ref MD: AKM MOSHARRAF HOSSAIN  
 Acq Tm: 11:59 AM  
 Pat Pos: HFS

Inst: BLM Tower Radiology  
 Ref MD: AKM MOSHARRAF HOSSAIN  
 Acq Tm: 11:59 AM  
 Pat Pos: HFS

Patient Name: WATTS GORDON  
 Accession Number: E09265692  
 Patient ID: 101222864  
 Exam Description: PET CT SKULL BASE TO MID THIGH

Exam no: 10030  
 Jul 12 2024  
 Discovery IQ

Dose Report

Series	Type	Scan Range (mm)	CTDIvol (mGy)	DLP (mGy-cm)	Phantom (cm)
1	Scout	-	-	-	-
2	Helical	120.000-1991.480	1.77	177.48	Body 32
Total Exam DLP:			177.48	177.48	

1/1

KV:  
 mA:  
 DFOV:  
 mm  
 TILT:

ALG:  
 CONT:  
 ZOOM: 100.00%  
 512x512