



Watts, Gordon Wayne, M, 05/16/1966

PLANT CITY FAMILY CARE

☐ 863-688-9880

801 E. Baker Street 340B00129100SC, Plant City, FL 33563-3652

☐ 813-349-7600

Accession ID: **40562959**

Lab Ref ID:

Order Date: **10/02/2023**

Collection Date: **13:51:00**

Requesting Physician: **Antigua Suarez, Nathaly**

Ordering Physician: **Antigua Suarez, Nathaly**

## PET CT IMAGING SKULL BASE TO THIGH

NAME

VALUE

See Below For Report

Patient: WATTS, GORDON W      DOB: 05/16/1966      Gender: M

CPP: 300994401

MRN: 3000128350

Account: 106011967224

Patient Status:

Admit Date: 10/02/2023

Location: South Florida Baptist Hospital  
Room

and Bed:

Requesting: Nathaly Antigua Suarez

Attending: Nathaly Antigua Suarez

Primary Care Provider: Robin Tiffany Burns-Thigpen

ACC: 40562959      Test Name: PET CT IMAGING SKULL BASE TO THIGH

Completed: 10/02/2023 13:51

PET CT IMAGING SKULL BASE TO THIGH

INDICATION: Prostate cancer.

COMPARISON: None.

TECHNIQUE: The glucose level for this patient was measured at 89 mg/dL. 11.58 mCi F-18 FDG was administered intravenously. Patient scanning started approximately one hour post injection of FDG. PET/CT scan was performed from the skull base to thighs. This consists of positron emission tomography supplemented by low dose CT for attenuation correction, anatomic correlation, and PET/CT image fusion.

FINDINGS:

METABOLIC IMAGING:

Reference mediastinal blood pool activity normalized for body weight: SUV max 2.1.

Focal hypermetabolic uptake in the left posterior aspect of the prostate gland, SUV max 7.0.

Mild low level FDG uptake in the anterior right fourth rib associated with vague sclerosis in this region, SUV max 2.0

NAME

VALUE

Remainder of FDG uptake is physiologic. No evidence of nodal metastasis.

NON-METABOLIC IMAGING:

Non contrast axial images performed for the purposes of attenuation correction.

2 mm right lower lobe nodule (4-69).

2 mm right middle lobe nodule (4-77).

No acute abnormality in the neck, chest, abdomen, or pelvis.

IMPRESSION:

Focal hypermetabolic uptake in the left posterior prostate gland, presumably corresponding with known prostate cancer.

Indeterminant low level FDG uptake in right anterior fourth rib favored to be posttraumatic, however metastasis cannot be entirely excluded. Correlate with history and for any evidence of focal tenderness. Otherwise, no evidence of osseous metastasis.

Two small nodules in the right lung, both measuring 2 mm. Could consider short-term follow-up depending on clinical concern. Comparison with prior imaging may be helpful and could obviate the need for additional imaging.

Electronically signed by Christopher Lazo on 10/2/2023 4:37 PM

Thank you for this referral.

Interpreted By: Christopher Ryan Lazo, RADIOLOGIST

Transcribed By: IA 10/02/2023

Electronically Signed By: Christopher Ryan Lazo, RADIOLOGIST 10/02/2023 04:39:00 pm

BayCare South Florida Baptist Hospital 301 N. Alexander Street Plant City, FL 33563 (813) 757-1260

---

Result:

Accession ID:

40562959

Notes:

WATTS~GORDON W - PET CT IMAGING SK...

Export Print Pan Windowing Annotations MPR Mode


Ref Lines Magnifier Image Info

Current Series

Original Negative Orientation Series Images Comparative Mode Groups Prev Series Next Series

Report	
3PET AC	PT
4CT 4.0 B38	CT
	242
5PET NAC	PT
	242
8PET Dose Report	PT
	2
502 Patient Protocol	CT
	1
603 Fused Tra	CT
	241
604 Fused Sag	CT
	111
605 Fused Cor	CT
	78
606 CINE MIP	PT
	32

300994401  
 WATTS~GORDON W  
 M  
 DOB: 5/16/1966  
 Age: 057Y



PET AC  
 SOUTH FLORIDA BAPTIST HOSPITAL  
 40562959  
 10/2/2023 1:08 PM  
 Ser:3  
 Im:1  
 Loc: S 61.50

WATTS~GORDON W - PET CT IMAGING SK...

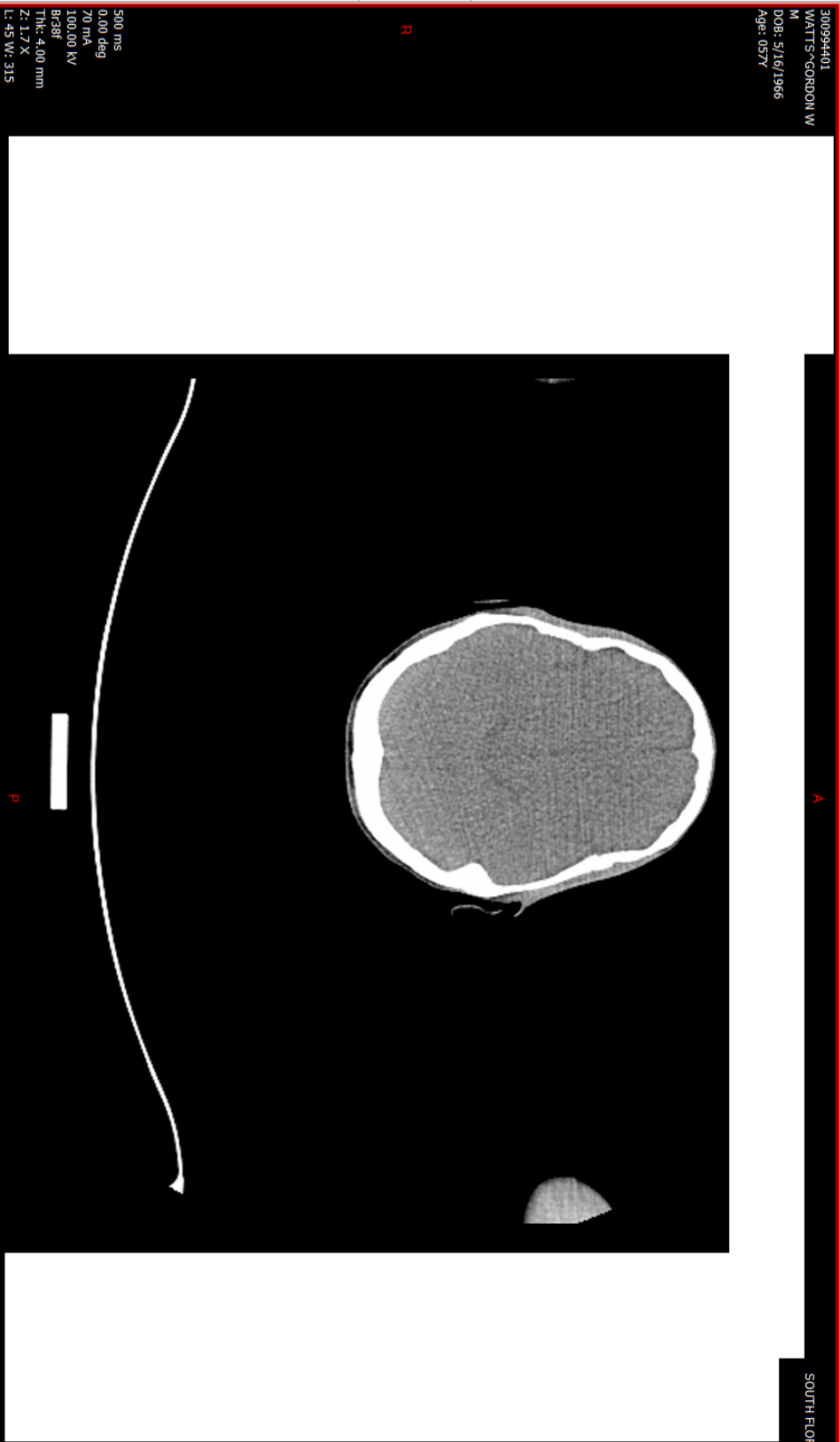
Export Print Pan Windowing Annotations MPR Mode

Ref Lines Magnifier Image Info

Current Series

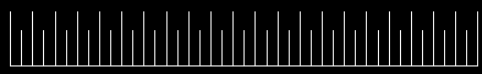
Original Negative Orientation Series Images Comparative Mode Groups Prev Series Next Series

Report	
3>PET AC	PT
242	
4 CT 4.0 B738	CT
242	
5>PET NAC	PT
242	
8>PET Dose Report	PT
2	
502 Patient Protocol	CT
1	
603 Fused Tra	CT
241	
604 Fused Sag	CT
111	
605 Fused Cor	CT
78	
606 CINE MIP	PT
32	



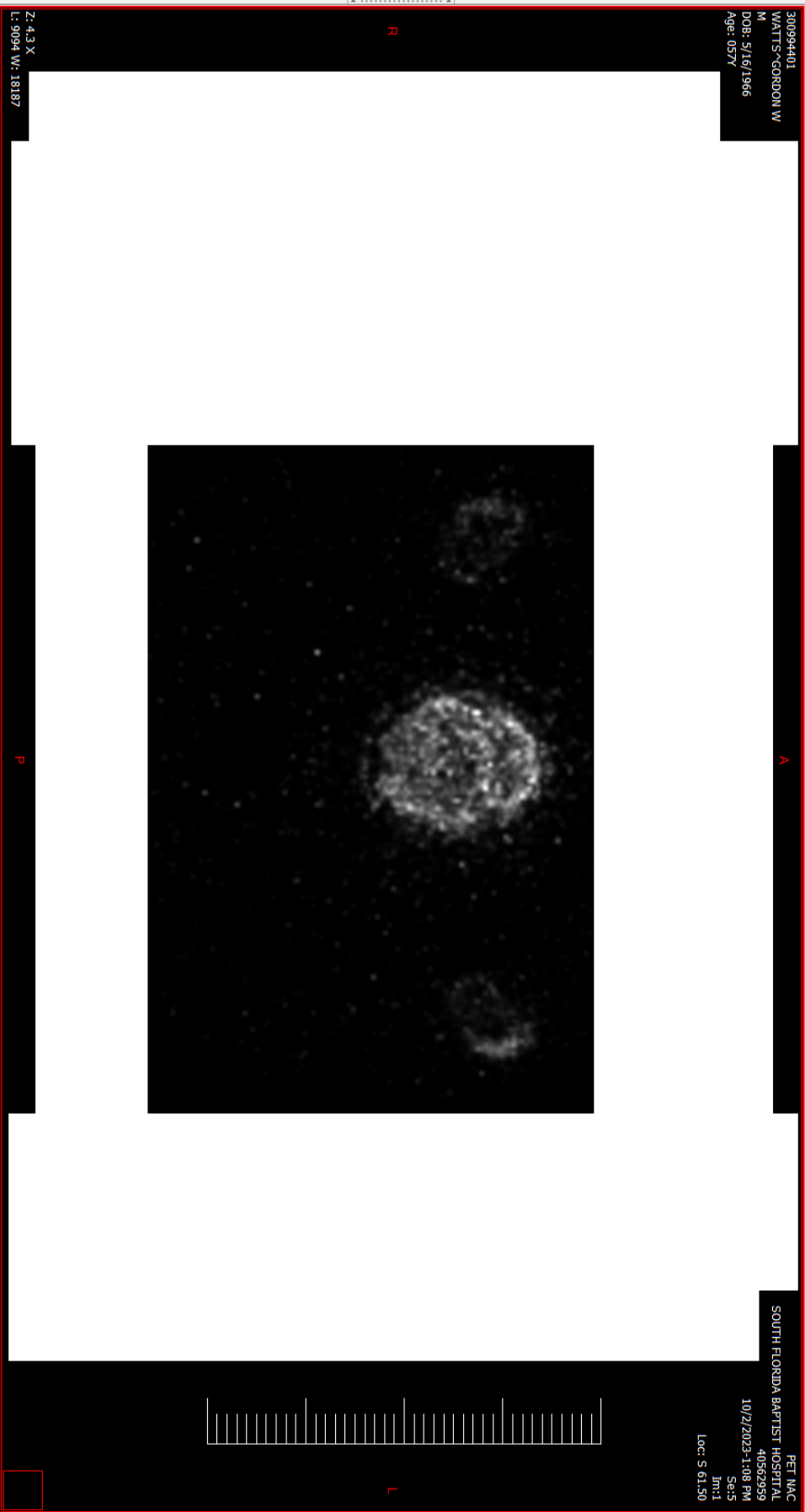
500 ms  
0.00 deg  
70 mA  
100.00 kV  
THK: 4.00 mm  
Z: 1.7 X  
BR28F  
L: 45 W: 315

CT 4.0 B738  
SOUTH FLORIDA BAPTIST HOSPITAL  
40562959  
10/2/2023 1:08 PM  
Ser: 4  
Im: 1  
Loc: S 61.50



Export Print Pan Windowing Annotations Zoom Original Negative Orientation Series Images Comparative Mode Groups Prev Series Next Series  
 Cine Ref Lines Magnifier Image Info MPR Mode Current Series

Report	
3 PET AC	PT
242	
4 CT 4.0 B-38	CT
242	
5 PET NAC	PT
242	
8 PET Dose Report	PT
2	
502 Patient Protocol	CT
1	
603 Fused Tra	CT
241	
604 Fused Sag	CT
111	
605 Fused Cor	CT
76	
606 CINE MIP	PT
32	



PET NAC  
 SOUTH FLORIDA BAPTIST HOSPITAL  
 40562959  
 10/2/2023-1:08 PM  
 Ser:5  
 Im:1  
 Loc: 5 61.50

Export Print Pan Windowing Annotations Zoom Original Negative Orientation Series Images Comparative Mode Groups Prev Series Next Series  
 One Ref Lines Magnifier Image Info MPR Mode Current Series

WATTS\*GORDON W - PET CT IMAGING SK...

Report	
3 PET AC	PT
242	
4 CT 4.0 B38	CT
242	
5 PET NAC	PT
242	
8 PET Dose Report	PT
2	
502 Patient Protocol	CT
1	
603 Fused Tra	CT
241	
604 Fused Sag	CT
111	
605 Fused Cor	CT
76	
606 CINE MIP	PT
32	

3000994401  
 WATTS\*GORDON W  
 M  
 DOB: 5/16/1966  
 Age: 057Y  
 Z: 1.7 X  
 L: 2048 W: 512

### PET Dose Report

RadioPharmaceutical	Fluorodeoxyglucose
Radioisotope	F-18
Radioisotope Half Life(s)	6586.2
Inj. Start Date(DD-MM-YYYY)	02-10-2023
Inj. Start Time(HH:MM:SS)	12-16-17
Inj. Stop Date(DD-MM-YYYY)	02-10-2023
Inj. Stop Time(HH:MM:SS)	12-16-17
Study Name	PET*SKULLBASE_MIDTHIGH (Adult)

Parameter	SI units	English units
Injected Dose	428.46 MBq	11.58 mCi
Weight	54.43 Kg	120.00 lbs
Height	1.73 m	5.67 ft
Blood Glucose	6.67 mmol/L	120.00 mg/dL
Effective Dose	8.14 mSv	814.07 mrem

PET Dose Report  
 Baptist Hospital  
 40562959  
 10/2/2023-N/A  
 Ser:8  
 Im:2001  
 Loc: N/A

Export Print Pan Windowing Annotations Zoom Original Negative Orientation Series Images Comparative Mode Groups Prev Series Next Series  
 Cine Ref Lines Magnifier Image Info MPR Mode Current Series

Report	
3 PET AC	PT 242
4 CT 4.0 B38	CT 242
5 PET NAC	PT 242
8 PET Dose Report	PT 2
502 Patient Protocol	CT 1
603 Fused Tra	CT 241
604 Fused Sag	CT 111
605 Fused Cor	CT 76
606 CINE MIP	PT 32

300094401  
 WATTS-GORDON W  
 M  
 DOB: 5/16/1966  
 Age: 057Y

```

02-Oct-2023 12:53
Ward:
Physician:
Operator:
Total mas 2977 Total DLP 229 mGycm
Scan KV mas / ref. CTDIvol* DLP TI cSL
mGy mGycm s mm
Patient Position H-SP 1 100 36 mA 0.05 L 4.8 5.9 0.6
Topogram CT 2 100 53 /128 2.29 L 224.0 0.5 1.2
PET
  
```

N/A ms  
 N/A deg  
 N/A mAs  
 N/A KV  
 N/A  
 Tks: N/A mm  
 Z: 1.7 X  
 L: 200 W: 50

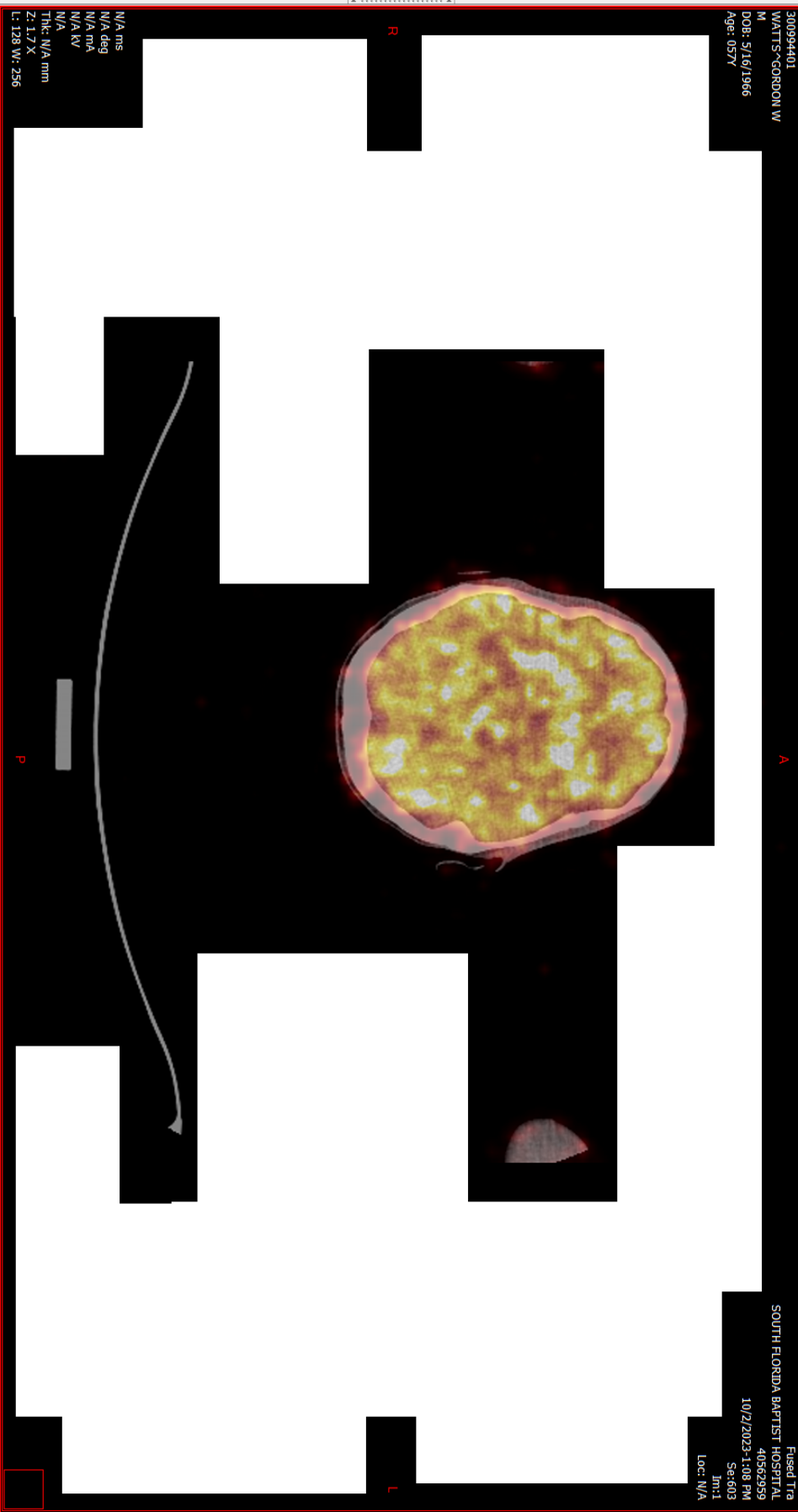
\* L = 32cm, S = 16cm

Patient Protocol  
 SOUTH FLORIDA BAPTIST HOSPITAL  
 40562959  
 10/2/2023-N/A  
 S6:502  
 Int:1  
 Loc: N/A

Cine | Ret Lines | Magnifier | Image Info | MPR Mode | Current Series

Export | Print | Pan | Windowing | Annotations | Zoom | Original | Negative | Orientation | Series | Images | Comparative Mode | Groups | Prev Series | Next Series

Report	
3 PET AC	PT 242
4 CT 4.0 B38	CT 242
5 PET NAC	PT 242
8 PET Dose Report	PT 2
502 Patient Protocol	CT 1
603 Fused Tra	CT 241
604 Fused Sag	CT 111
605 Fused Cor	CT 76
606 CINE MIP	PT 32

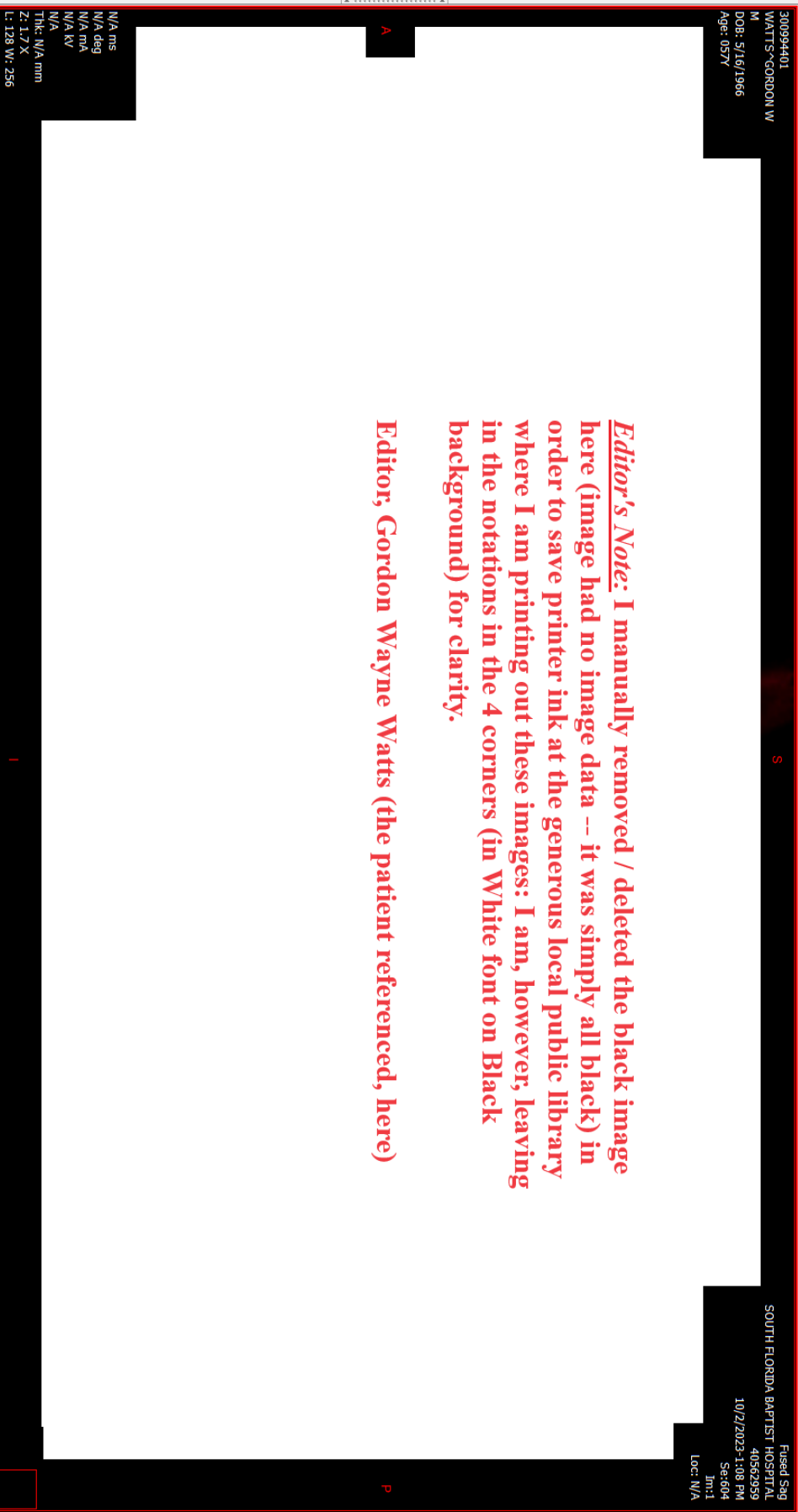


N/A ms  
 N/A deg  
 N/A mAs  
 N/A kV  
 N/A  
 Tks: N/A mm  
 Z: 1.7 X  
 L: 128 W: 256

Fused Tra  
 SOUTH FLORIDA BAPTIST HOSPITAL  
 40562959  
 10/2/2023 1:08 PM  
 S6:603  
 Im:1  
 Loc: N/A

Export Print Pan Windowing Annotations Zoom Original Negative Orientation Series Images Comparative Mode Groups Prev Series Next Series  
 Cine Ref Lines Magnifier Image Info MPR Mode Current Series

Report	
3 PET AC	PT 242
4 CT 4.0 B38	CT 242
5 PET NAC	PT 242
8 PET Dose Report	PT 2
502 Patient Protocol	CT 1
603 Fused Tra	CT 241
604 Fused Sag	CT 111
605 Fused Cor	CT 76
606 CINE MIP	PT 32



*Editor's Note: I manually removed / deleted the black image here (image had no image data -- it was simply all black) in order to save printer ink at the generous local public library where I am printing out these images: I am, however, leaving in the notations in the 4 corners (in White font on Black background) for clarity.*

**Editor, Gordon Wayne Watts (the patient referenced, here)**

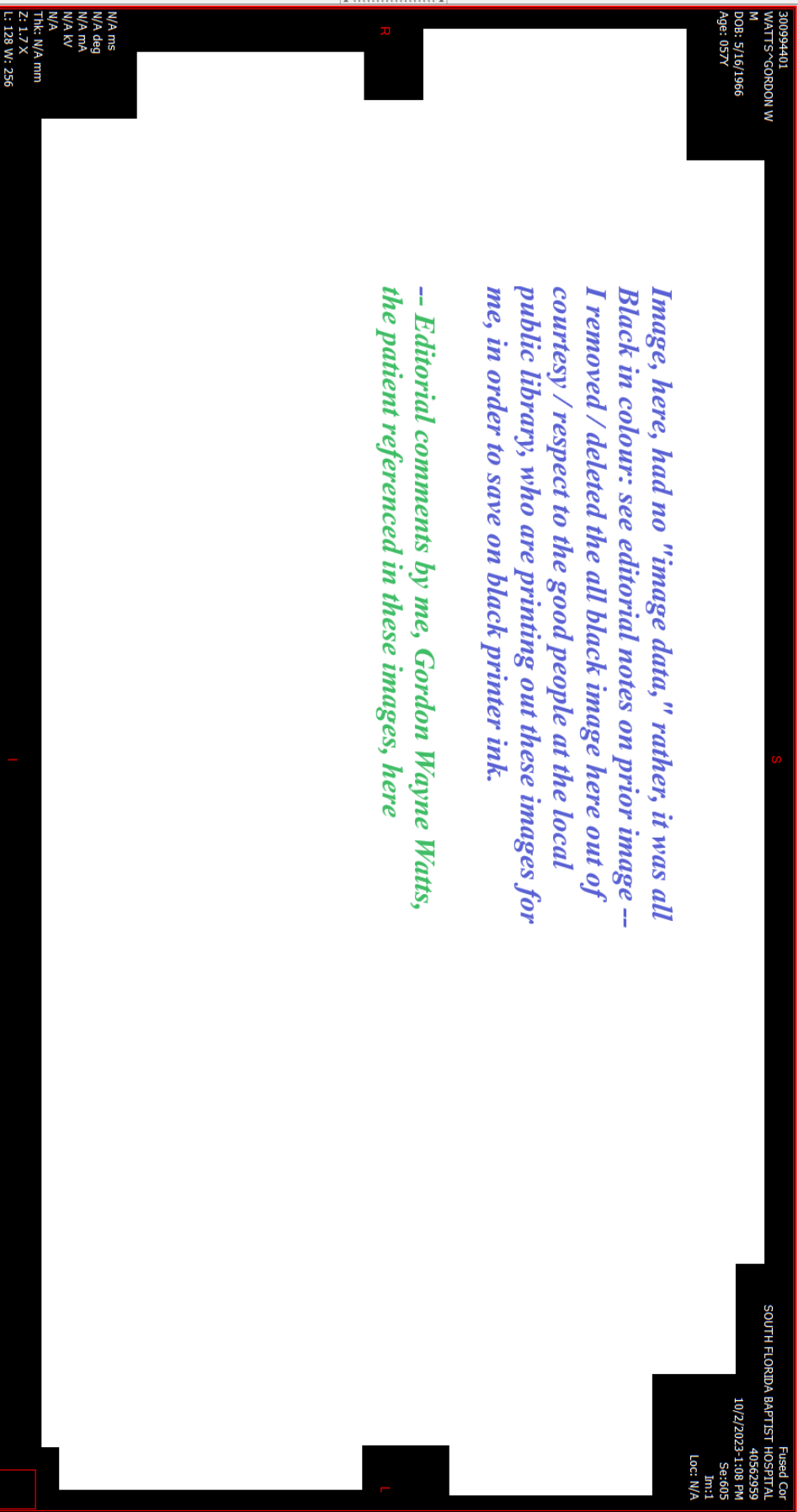
N/A ms  
 N/A deg  
 N/A mAs  
 N/A kV  
 N/A  
 Ttk: N/A mm  
 Z: 1.7 X  
 L: 128 W: 256

Fused Sag  
 SOUTH FLORIDA BAPTIST HOSPITAL  
 40562959  
 10/2/2023 1:08 PM  
 Se:604  
 Im:1  
 Loc: N/A

Export Print Annotations Windowing Magnifier Image Info MPR Mode  
 Ret Lines Magnifier Image Info MPR Mode  
 Original Negative Orientation Series Images Comparative Mode Groups Prev Series Next Series  
 Current Series

WATTS^GORDON W - PET CT IMAGING SK...

Report	
3 PET AC	PT
242	
4 CT 4.0 B-38	CT
242	
5 PET NAC	PT
242	
8 PET Dose Report	PT
2	
502 Patient Protocol	CT
1	
603 Fused Tra	CT
241	
604 Fused Sag	CT
111	
605 Fused Cor	CT
76	
606 CINE MIP	PT
32	



*Image, here, had no "image data," rather, it was all  
 Black in colour: see editorial notes on prior image --  
 I removed / deleted the all black image here out of  
 courtesy / respect to the good people at the local  
 public library, who are printing out these images for  
 me, in order to save on black printer ink.*

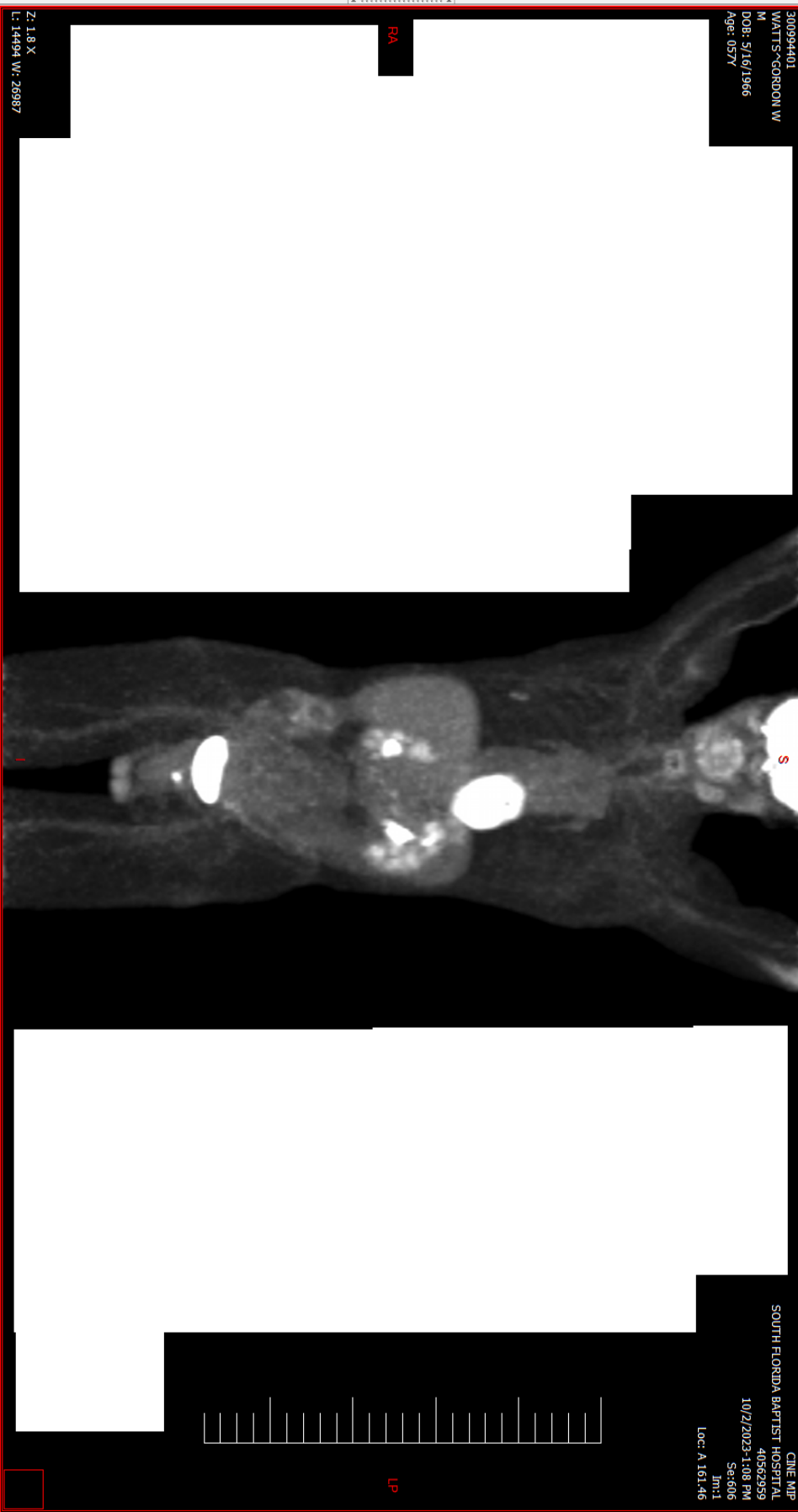
*-- Editorial comments by me, Gordon Wayne Watts,  
 the patient referenced in these images, here*

N/A ms  
 N/A deg  
 N/A nra  
 N/A kv  
 N/A  
 Ttk: N/A mm  
 Z: 1.7 X  
 L: 128 W: 256

Fused Cor  
 SOUTH FLORIDA BAPTIST HOSPITAL  
 40562959  
 10/2/2025 1:08 PM  
 S6:605  
 Im:1  
 Loc: N/A

Cine | Ret Lines | Magnifier | Image Info | MPR Mode | Current Series  
 Export | Print | Pan | Windowing | Annotations | Zoom | Original | Negative | Orientation | Series | Images | Comparative Mode | Groups | Prev Series | Next Series

Report	
3 PET AC	PT
242	
4 CT 4.0 B38	CT
242	
5 PET NAC	PT
242	
8 PET Dose Report	PT
2	
502 Patient Protocol	CT
1	
603 Fused Tra	CT
241	
604 Fused Sag	CT
111	
605 Fused Cor	CT
76	
606 Cine MIP	PT
32	



3000994401  
 WATTS-GORDON W  
 M  
 DOB: 5/16/1966  
 Age: 057Y

Cine MIP  
 SOUTH FLORIDA BAPTIST HOSPITAL  
 40562959  
 10/2/2023 1:08 PM  
 Seq:606  
 Im:1  
 Loc: A 161.46

Z: 1.8 X  
 L: 14494 W: 26987