

LABORATORY REPORT

5032 AREA/ROUTE/ST. J 30TR550
 DOVER CLINIC
 RUSKIN MIGRANT & COMM HLTH CTR
 P O BOX DC HWY 574
 DOVER, FL 33527

SB SmithKline Beecham
 Clinical Laboratories

MICROFILM# 06219417910

PATIENT NAME WATTS, GORDON		PATIENT ID 051666		ROOM NO.	AGE 28	SEX M	PHYSICIAN ESTRADA, #20
PAGE 1	REQUISITION NO. 3754925	ACCESSION NO. 341958K	LAB REF. #	COLLECTION DATE & TIME 06/21/94	LOG-IN-DATE 06/21/94	REPORT DATE 06/22/94	& TIME 6:37AM

REMARKS

1994 (06/21/1994)

REPORT STATUS	TEST	RESULT		UNITS	REFERENCE RANGE
		IN RANGE	OUT OF RANGE		
FINAL	THYROID PANEL, HYPO				
	THYROID PANEL				
	T-4 (THYROXINE), TOTAL	9.4		MCG/DL	4.5 - 12.5
	T-3 UPTAKE	29		x	24 - 37
	FTI (T7)	2.7		RATIO	1.4 - 3.8
	THYROID STIMULATING HORMONE, HIGHLY SENS.	2.0		MCIU/ML	0.4 - 5.5
	CHEMISTRY PANEL #1				
	GLUCOSE	90		MG/DL	70 - 115
	UREA NITROGEN (BUN)	10		MG/DL	7 - 25
	CREATININE	1.3		MG/DL	0.7 - 1.4
	BUN/CREATININE RATIO	8		RATIO (CALC)	6 - 25
	SODIUM	142		MEQ/L	135 - 146
	POTASSIUM	4.2		MEQ/L	3.5 - 5.3
	CHLORIDE	104		MEQ/L	95 - 108
	MAGNESIUM	1.6		MEQ/L	1.2 - 2.0
	CALCIUM	9.1		MG/DL	8.5 - 10.3
	PHOSPHORUS	3.1		MG/DL	2.5 - 4.5
	PROTEIN, TOTAL	7.6		G/DL	6.0 - 8.5
	ALBUMIN	4.6		G/DL	3.2 - 5.0
	GLOBULIN, TOTAL	3.0		G/DL (CALC)	2.2 - 4.2
	A/G RATIO	1.5		RATIO (CALC)	0.8 - 2.0
	BILIRUBIN, TOTAL	0.5		MG/DL	0.0 - 1.3
	ALKALINE PHOSPHATASE	56		U/L	20 - 125
	LACTATE DEHYDROGENASE	140		U/L	0 - 250
	GGTP	13		U/L	0 - 65
	AST (SGOT)	21		U/L	0 - 42
	ALT (SGPT)	13		U/L	0 - 40
	URIC ACID		3.3 L	MG/DL	4.0 - 8.5
	IRON, TOTAL	90		MCG/DL	25 - 170
	TRIGLYCERIDES	72		MG/DL	< 200
	CHOLESTEROL, TOTAL	153		MG/DL	< 200
	RAPID PLASMA REAGIN (RPR)	NONREACTIVE			NONREACTIVE

>> END OF REPORT <<

Watts, Gordon

821 Alicia Rd, Lakeland, FL, US 33801

DOB: 05/16/1966 Age: 45 Y Sex: male

Home: 863-688-9880

Work:

Cell:

Email:

Primary Insurance: Community Health & Social Services
PCP: Pedro Ruiz

Allergies : N.K.D.A

01/19/2011

Medical History

Active Problem List

Code	Name	Specify	Notes	Added On	Modified On	Modified By
426.4	Right bundle branch block				01/19/2011	Patheja, Harpreet K
784.0	Headache				01/19/2011	Patheja, Harpreet K
794.8	Abnormal Liver Function Tests				02/02/2011	Patheja, Harpreet K

2011

Past Medical History

cataracts left eye
Cataract, nuclear sclerosis

Medications

Name strength formulation, Sig: take route frequency

Aspirin 162 MG Tablet Delayed Release, Sig: 1 tablet as needed Orally every 4 hrs
Multi Vitamin Mens Tablet, Sig: as directed Orally

Surgical History

Date	Reason
	hand surgery

Hospitalization

Date	Reason
	pneumonia

Social History

Name	Value
Annual Release of Medical Information	Date 3/29/2011
Alcohol Screening:	Points: 0, Interpretation: Negative
Illicit Drug use:	Illicit Drugs: Denies use of illicit drugs
Language:	Language English
Living with:	father
Marital Status:	SINGLE
Occupation:	unemployed
Pets:	cats:4
Religion:	Religion Christian Unspecified
Sexual Hx:	Had sex in the last 12 months (vaginal, oral, or anal)?: No
Smoking:	Smoking never smoker

Family History

Relation : Description

Father: alive heart attack
Mother: alive
Grand Parents: deceased
Siblings: none
Children: none

Vitals

Name	Date	Value
Temp	06/13/2011	98.6
RR	06/13/2011	16
Ht	06/13/2011	70
Wt	06/13/2011	129.0
BMI	06/13/2011	18.51
BP sitting	06/13/2011	100/70
Pulse sitting	06/13/2011	80
Smoking	06/13/2011	no

Health Maintenance

Name	Last Done	DueDate	Result/Comment
------	-----------	---------	----------------

Watts, Gordon

821 Alicia Rd, Lakeland, FL, US 33801

DOB: 05/16/1966 **Age:** 45 Y **Sex:** male

Home: 863 688 9880

Work:

Cell:

Email:

Primary Insurance: Community Health & Social Services

PCP: Pedro Ruiz

Allergies : N.K.D.A

Annual Physical		06/27/2011
Chest X-ray PA and lateral		06/27/2011
ECG - EKG - Electrocardiogram	01/20/2011	01/20/2012
FLU VACCINE		06/27/2011
PSA		06/27/2011
TSH	01/19/2011	01/19/2016

TSH	
COLLECTION DATE	01/19/2011
ORDER DATE	01/19/2011
RESULT DATE	01/20/2011
ORDERING PHYSICIAN	Pedro Ruiz
TSH	2.970 (0.450-4.500 uIU/mL)

Patient: Watts, Gordon DOB: 05/16/1966

2011

01/19/2011



HIGHLAND
LAKELAND

PATIENT NUMBER: LL119387
PATIENT: WATTS, GORDON
DATE OF BIRTH: 05/16/1966
PHYSICIAN: MICHAEL STRICKLAND ARNP
DATE: 11/18/2011
EXAMINATION: XR L-SPINE

11/18/2011

TECHNIQUE: Five views.

FINDINGS: Mild to moderate dextroscoliosis of the lumbar spine is seen. The stature of the lumbar vertebral bodies and disc spaces is well preserved with no fracture, dislocation, lytic or blastic lesion. No significant arthritic change is seen. The pedicles are intact.

IMPRESSION:

1. LEVOSCOLIOSIS OF A MILD TO MODERATE DEGREE.
2. NO ACUTE BONY ABNORMALITY OR SOFT TISSUE ABNORMALITY IS SEEN INVOLVING THE LUMBAR SPINE.

Thank you for this referral.

Thomas A. Okulski, M.D.
Diplomate, American Board of Radiology
Fellowship Trained in Vascular and Interventional Radiology
Dictated but not reviewed to expedite delivery

TO/axiommti6
dd: 11/19/2011
dt: 11/19/2011

Dictated and Electronically Signed by:
Thomas Okulski, MD

Received by me
Tuesday, 22 November 2011
Gordon Wayne Watts
Gordon Wayne Watts
From Dr. Pedro Ruiz
office

11/18/2011

11/18/2011

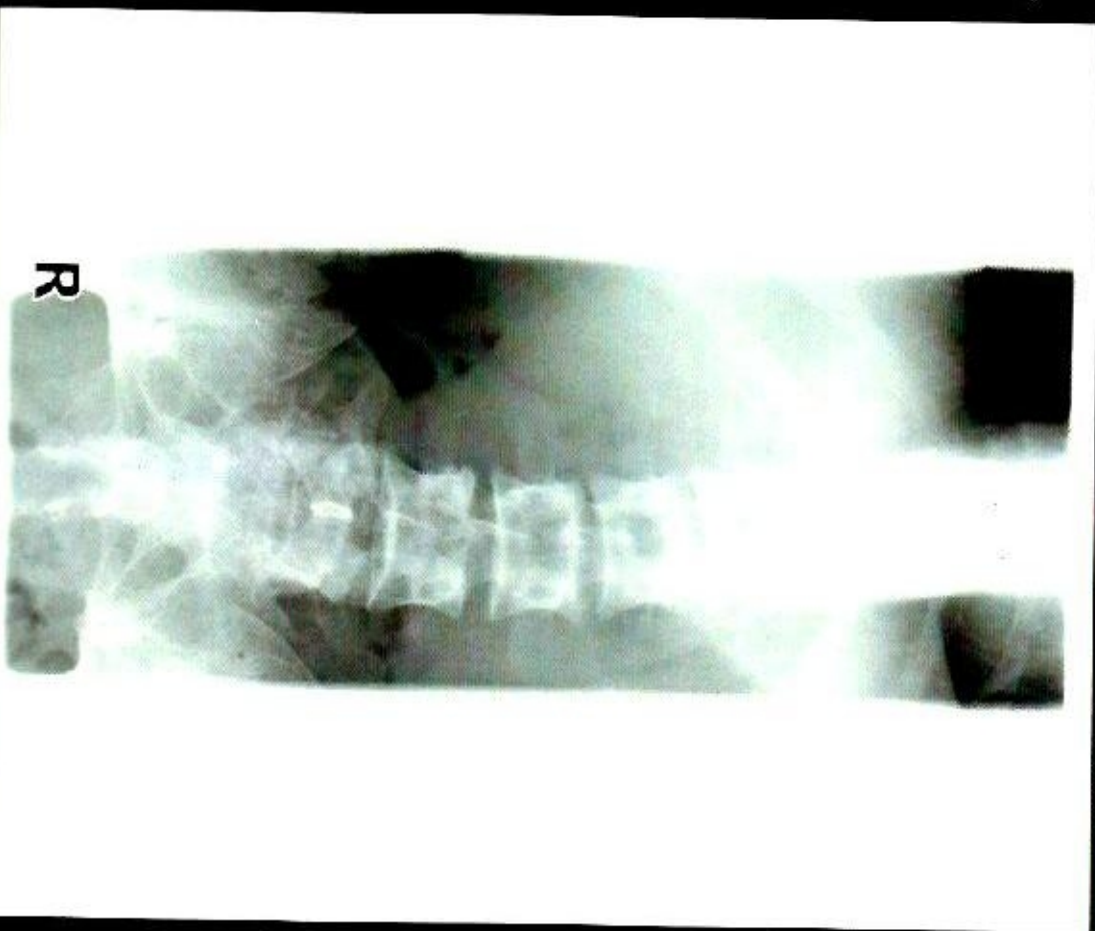
Genesis

File Edit View Image Process Tool Options Help


1119387 WATTS-GORDON M 45Y 18 L-SPINE 20111118 2

1
LL119387
WATTS-GORDON M / 45Y
BD: 1966.05.16

SE: 1
IM: 1
ACG#: 2011111816031383
W 1914 : L 3144



HIGHLAND MRI
XR L-SPINE
2011.11.18
16:14:46

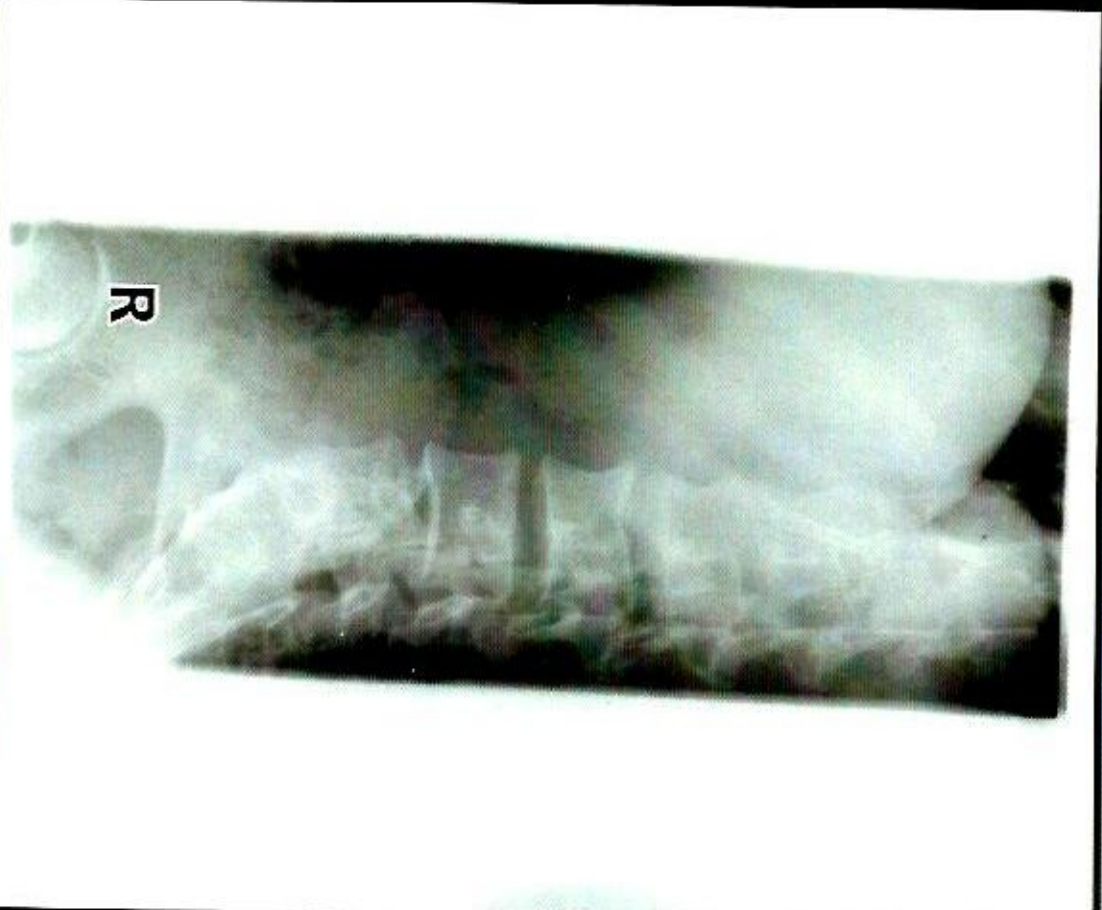


All Series

11/18/2011

2
L1119387
WATTS+GORDON M / 45Y
BD: 1966.05.16

SE: 1
IM: 2
ACQ#: 2011111816031383
W 3254 : L 2460



HIGHLAND MRI
XR L-SPINE
2011.11.18
16:14:48

10cm

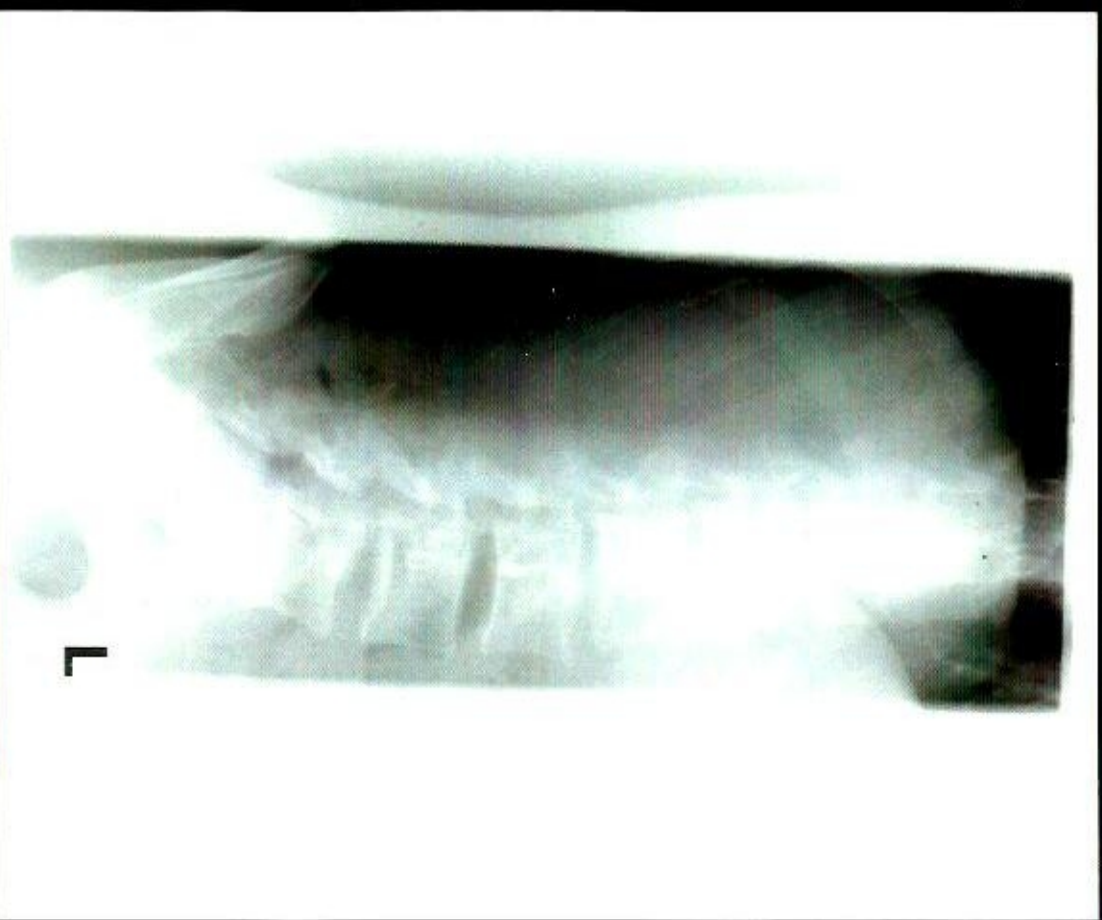WATTS+GORDON
DR LESPIE XR

11-18-2011



3
LL118397
WATTS+GORDON M / 45Y
BD: 1966.05.16

SE: 1
IM: 3
ACQ#: 2011111816031383
W 4085 : L 2044



HIGHLAND MRI
XR L-SPINE
2011.11.18
16:14:51



11/18/2011

Genesis

File Edit View ImageProcess Tool Open Help

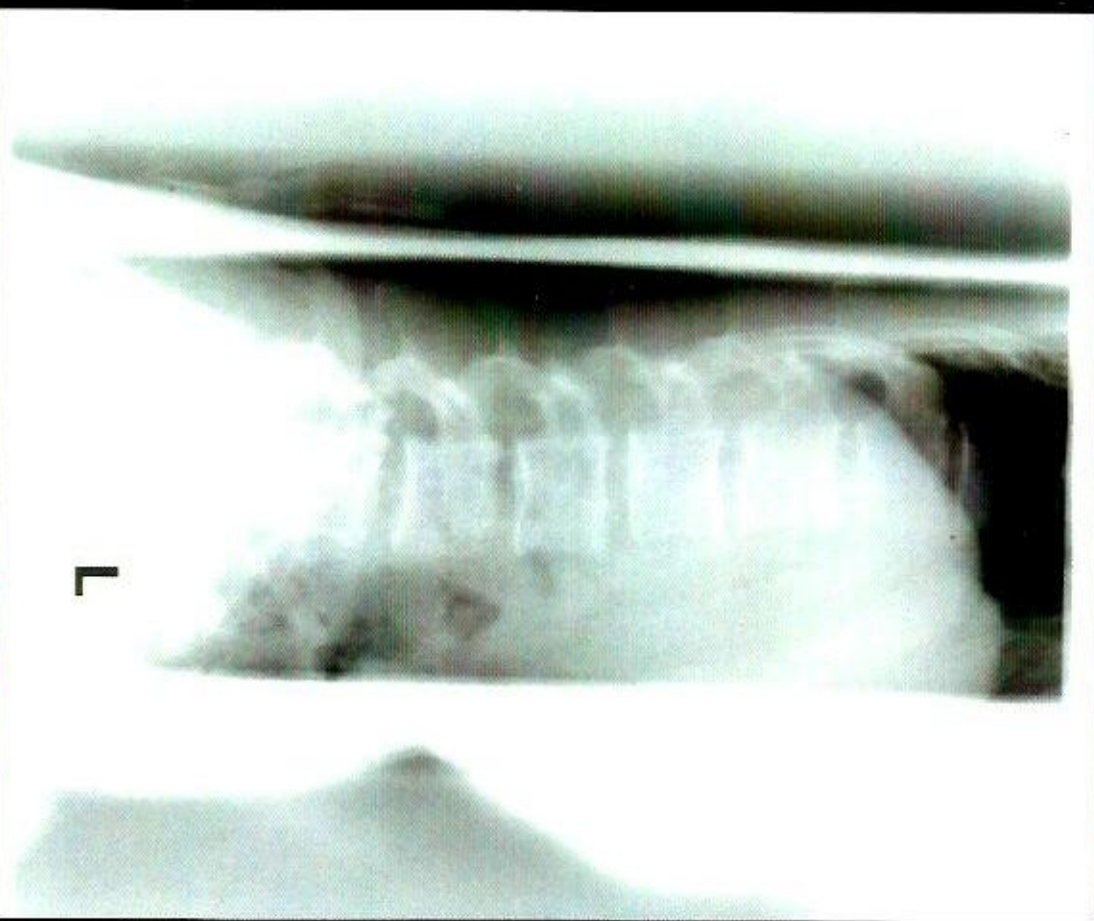
LL119387 WATTS/GORDON M 45Y 18 L-SPINE 20111118 4

All Series

4
LL119387
WATTS/GORDON M / 45Y
BD: 1966.05.16

HIGHLAND MRI
XR L-SPINE
2011.11.18
16:14:53

SE: 1
IM: 4
ACCA#: 2011111816031383
W 3798 : L 1903



100cm

11-2-2011 2011

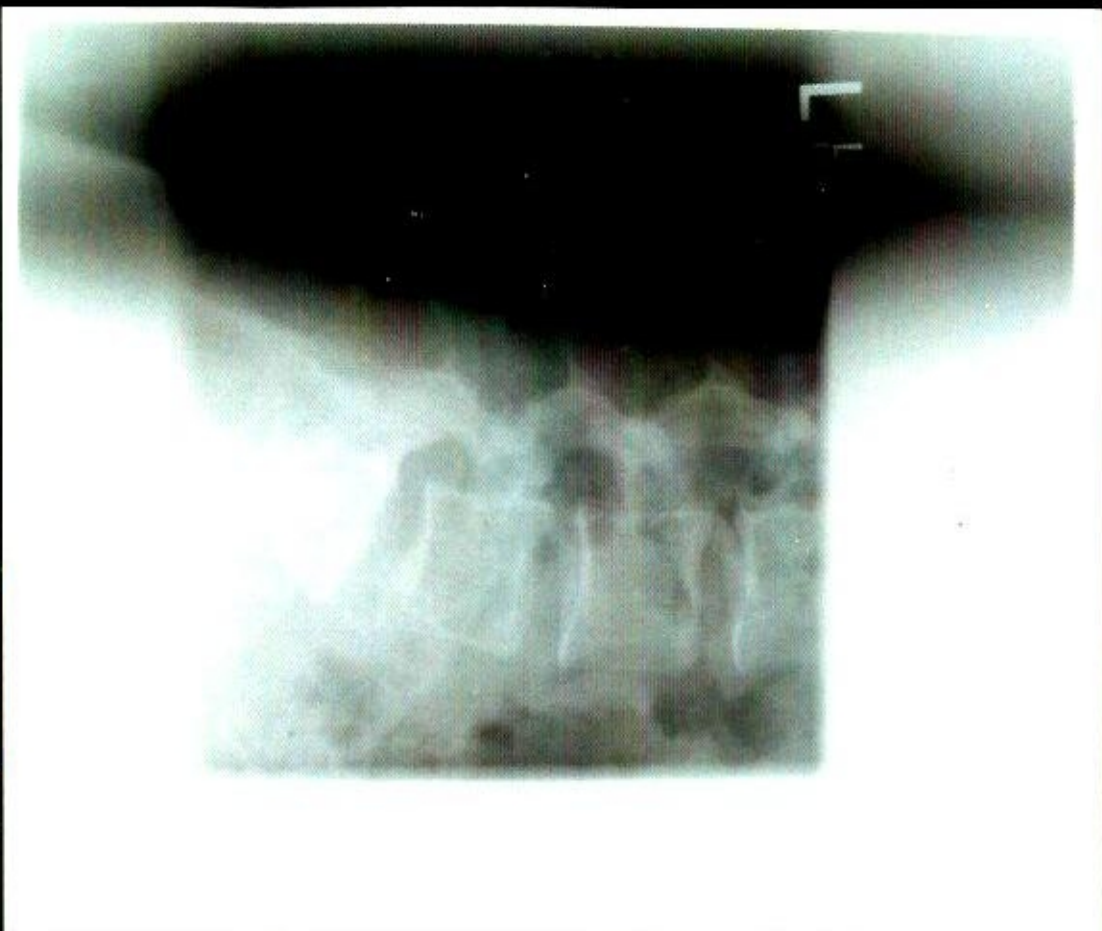Genesis

File Edit View Inspector Tools Color Help

LL119387 WATTS+GORDON M d57 J8 L-SPINE 20111118 4

5
LL119387
WATTS+GORDON M / 45Y
BD: 1966.05.16

SE: 1
IM: 5
ACQ#: 2011111816031383
W 3627 : L 2873



HIGHLAND MRI
XR L-SPINE
2011.11.18
16:14:55

10cm

All Series



WATTS+GORDON
CELLESPINE JB


Ready

SPINE VIEWER

100%

11/2/2011 11:20 AM

Subj: **Appointment Confirmation from your doctor's office**
Date: 4/5/2013 3:55:31 P.M. Eastern Daylight Time
From: reminders@eclinicalmail.com
To: gww1210@aol.com



Patient: Gordon Watts

Appointment Date: 06/20/2013, 3:45 PM

Practice: WellMed At SE Lakeland

Practice Phone: 863-666-9020

Special Instructions:

Please bring all your medications in their respective bottles with you to each visit, so we can ensure that you are taking your medications as recommended. We appreciate your trust in our office as your healthcare providers. If you have any questions or need to reschedule, please call our office during regular business hours.

For directions click [here](#).

Powered By eClinicalWorks

CONFIDENTIALITY NOTICE AND DISCLAIMER: This transmission contains confidential information belonging to the sender that is legally privileged and proprietary and may be subject to protection under the law, including the Health Insurance Portability and Accountability Act (HIPAA). If you are not the intended recipient of this e-mail, you are prohibited from sharing, copying, or otherwise using or disclosing its contents. If you have received this e-mail in error, please delete this e-mail and any attachments without reading, forwarding or saving them. Thank you.

If you don't want to receive these emails from us in the future, you can [Unsubscribe](#).

Patient Name: Watts, Gordon W
 Date of Birth: 05/16/1966
 Telephone: 863-688-9880

Pedro Ruiz MD
 4740 Exploration Ave
 FL-33812
 863-666-9020

04/05/2013

2013

Hemoglobin A1c	
COLLECTION DATE	04/05/2013
ORDER DATE	04/05/2013
RESULT DATE	04/09/2013
ORDERING PHYSICIAN	Michael L Strickland
Hemoglobin A1c	5.2 (4.8-5.6 %)

CBC with Differential/Platelet	
COLLECTION DATE	04/05/2013
ORDER DATE	04/05/2013
RESULT DATE	04/09/2013
ORDERING PHYSICIAN	Michael L Strickland
WBC	6.3 (4.0-10.5 x10E3/uL)
RBC	3.97 (4.14-5.80 x10E6/uL) L
HEMOGLOBIN	12.4 (12.6-17.7 g/dL) L
HEMATOCRIT	37.5 (37.5-51.0 %)
MCV	95 (79-97 fL)
MCH	31.2 (26.6-33.0 pg)
MCHC	33.1 (31.5-35.7 g/dL)
RDW	13.6 (12.3-15.4 %)
PLATELET COUNT	290 (140-415 x10E3/uL)
ABSOLUTE NEUTROPHILS	4.5 (1.8-7.8 x10E3/uL)
NEUTROPHILS %	72 (40-74 %)
ABSOLUTE LYMPHOCYTES	1.0 (0.7-4.5 x10E3/uL)
LYMPHOCYTES %	15 (14-46 %)
ABSOLUTE MONOCYTES	0.4 (0.1-1.0 x10E3/uL)
MONOCYTES %	6 (4-13 %)
ABSOLUTE EOSINOPHILS	0.4 (0.0-0.4 x10E3/uL)
EOSINOPHILS %	6 (0-7 %)
ABSOLUTE BASOPHILS	0.0 (0.0-0.2 x10E3/uL)
BASOPHILS %	1 (0-3 %)

VITAMIN B12	
COLLECTION DATE	04/05/2013
ORDER DATE	04/05/2013
RESULT DATE	04/09/2013
ORDERING PHYSICIAN	Michael L Strickland
VITAMIN B12	>1999 (211-946 pg/mL) H

Lipid Panel	
COLLECTION DATE	04/05/2013
ORDER DATE	04/05/2013

Patient: Watts, Gordon W DOB: 05/16/1966

RESULT DATE	04/09/2013
ORDERING PHYSICIAN	Michael L Strickland
Cholesterol, Total	137 (100-199 mg/dL)
Triglycerides	49 (0-149 mg/dL)
HDL Cholesterol	55 (>39 mg/dL)
LDL Cholesterol Calc	72 (0-99 mg/dL)
VLDL Cholesterol Cal	10 (5-40 mg/dL)

Fat
Good Cholesterol
Bad Cholesterol

Ferritin	
COLLECTION DATE	04/05/2013
ORDER DATE	04/05/2013
RESULT DATE	04/09/2013
ORDERING PHYSICIAN	Michael L Strickland
FERRITIN	44 (30-400 ng/mL)

Iron

PSA	
COLLECTION DATE	04/05/2013
ORDER DATE	04/05/2013
RESULT DATE	04/09/2013
ORDERING PHYSICIAN	Michael L Strickland
PSA, Total	2.9 (0.0-4.0 ng/mL)

Prostate

Basic Metabolic Panel W/ GFR Ratio	
COLLECTION DATE	04/05/2013
ORDER DATE	04/05/2013
RESULT DATE	04/09/2013
ORDERING PHYSICIAN	Michael L Strickland
GLUCOSE	110 (65-99 mg/dL) H
BUN	16 (6-24 mg/dL)
CREATININE	0.95 (0.76-1.27 mg/dL)
BUN/CREATININE RATIO	17 (9-20)
GFR AFRICAN AMERICAN	111 (>59 mL/min/1.73)
GFR NON-AFRICAN AMER	96 (>59 mL/min/1.73)
SODIUM	140 (134-144 mmol/L)
POTASSIUM	4.0 (3.5-5.2 mmol/L)
CHLORIDE	107 (97-108 mmol/L)
CARBON DIOXIDE	25 (20-32 mmol/L)
CALCIUM	8.7 (8.7-10.2 mg/dL)

Kidney

Liver Function Tests - LFT's	
COLLECTION DATE	04/05/2013
ORDER DATE	04/05/2013
RESULT DATE	04/09/2013
ORDERING PHYSICIAN	Michael L Strickland
Total Protein	6.1 (6.0-8.5 g/dL)
Albumin	4.1 (3.5-5.5 g/dL)

Patient: Watts, Gordon W DOB: 05/16/1966

BILIRUBIN TOTAL	0.2 (0.0-1.2 mg/dL)
BILIRUBIN DIRECT	0.10 (0.00-0.40 mg/dL)
ALKALINE PHOSPHATASE	56 (25-150 IU/L)
AST (SGOT)	18 (0-40 IU/L)
ALT (SGPT)	13 (0-44 IU/L)

TSH	
COLLECTION DATE	04/05/2013
ORDER DATE	04/05/2013
RESULT DATE	04/09/2013
ORDERING PHYSICIAN	Michael L Strickland
TSH	2.280 (0.450-4.500 uIU/mL)

Folate (Folic Acid), Serum	
COLLECTION DATE	04/05/2013
ORDER DATE	04/05/2013
RESULT DATE	04/09/2013
ORDERING PHYSICIAN	Michael L Strickland
Folate (Folic Acid), Serum	17.7 (>3.0 ng/mL)

Patient: Watts, Gordon W DOB: 05/16/1966



Handwritten notes: 04/08/2013 and 2013

PATIENT NUMBER: LL119387
PATIENT: WATTS, GORDON
DATE OF BIRTH: 05/16/1966
PHYSICIAN: MICHAEL STRICKLAND ARNP
DATE: 04/08/2013
EXAMINATION: XR CHEST

TECHNIQUE: Two views.

FINDINGS: The heart is not enlarged. The pulmonary vasculature is not engorged.

No consolidative change, effusion or parenchymal mass is noted. Mild hyperaeration is noted. Mild apical thickening, chronic in nature, on the left is noted.

Mild levoscoliosis of the mid upper dorsal spine is seen.

IMPRESSION:

- 1. CHRONIC CHANGE.
2. NO ACTIVE DISEASE IS SEEN WITHIN THE CHEST.

Thank you for this referral.

Thomas A. Okulski, M.D.
Diplomate, American Board of Radiology
Fellowship Trained in Vascular and Interventional Radiology
Dictated but not reviewed to expedite delivery

TO/axiommti6
dd: 04/08/2013
dt: 04/08/2013

Handwritten signature of Thomas A. Okulski

Dictated and Electronically Signed by:
Thomas Okulski, MD

HIGHLAND MRI
 ID: LL119387
 Name: WATTS^GORDON^
 DOB: 05/16/1966
 SEX: M
 DE: 04/08/2013
 Time: 15:03:37
 Man: Carestream Health, Inc.
 BP: CHEST

**I inverted the colours to
 save on printer ink.**

-- Gordon

04	08	2013
----	----	------

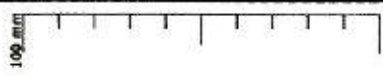
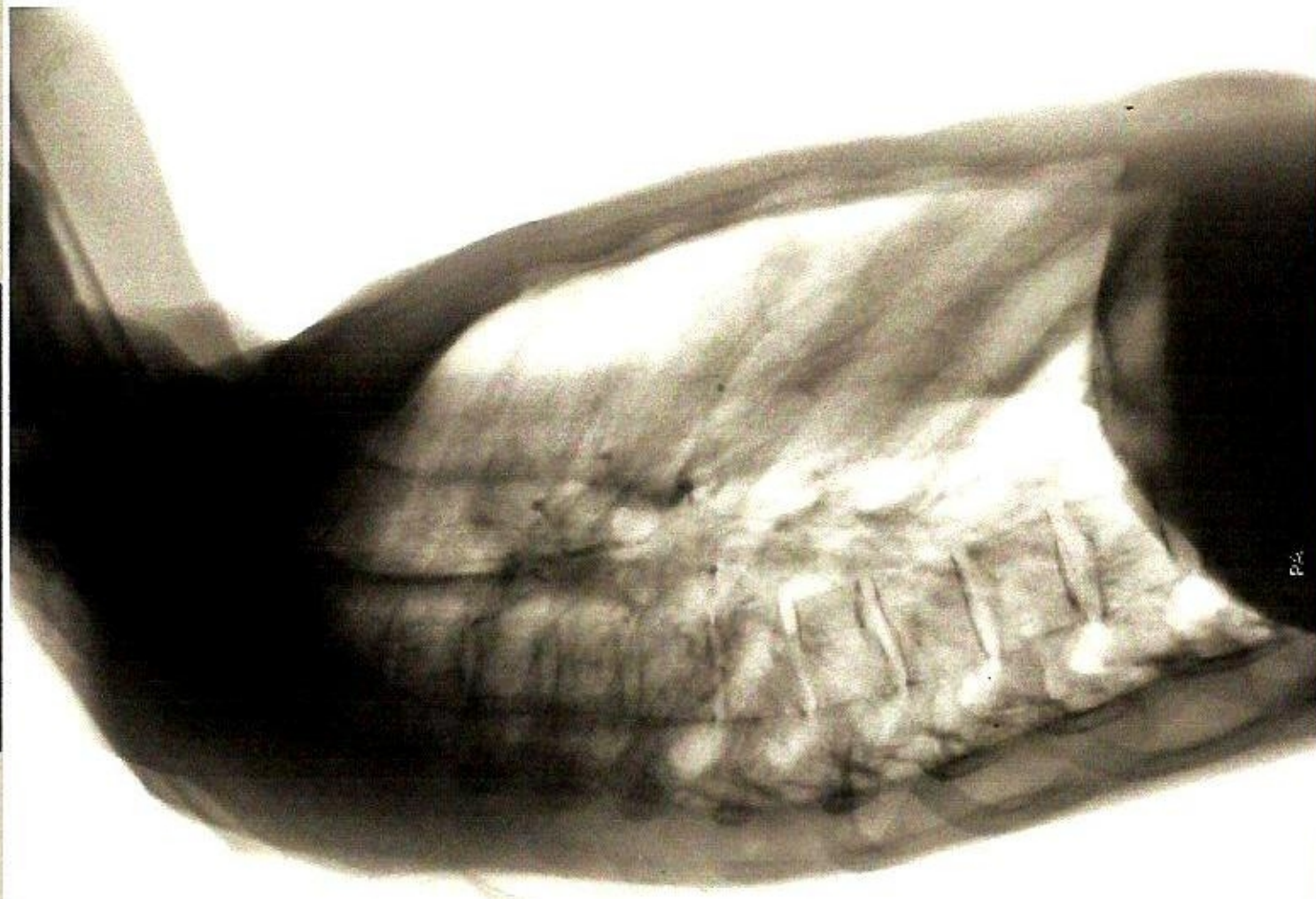

Image: 2
 VPos: LATERAL
 Q: 2107

FOV: 51.21 x 41.83cm
 MAG: 0.35 (1.00)
 W/L: 4095.00/2048.00

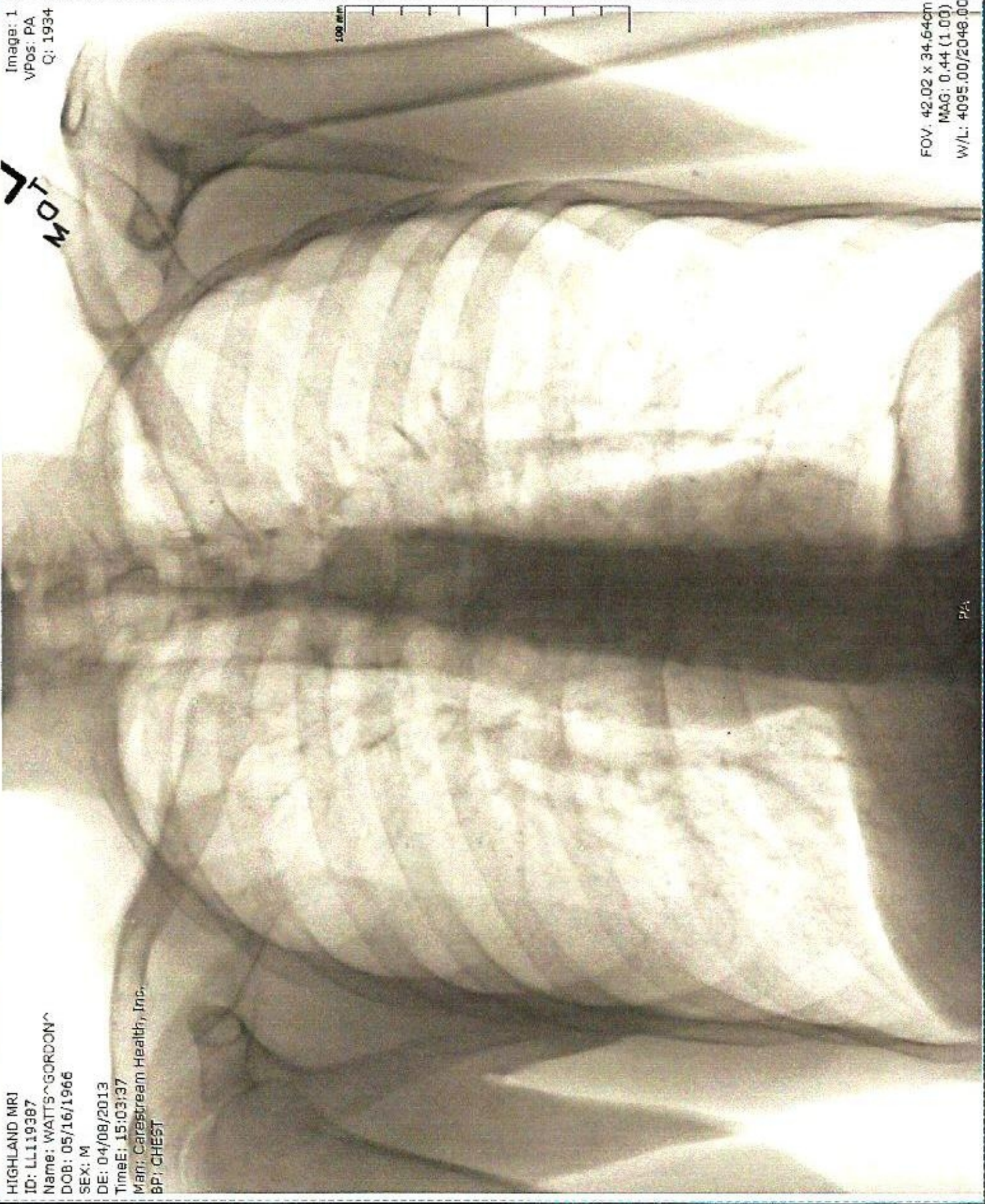
PA

HIGHLAND MRI
ID: LL119387
Name: WATTS^GORDON^
DOB: 05/16/1966
SEX: M
DE: 04/08/2013
TimeE: 15:03:37
Man: Carestream Health, Inc.
BP: CHEST

Image: 1
VPos: PA
Q: 1934

MOT

100 mm



FOV: 42.02 x 34.64cm
MAG: 0.44 (1.00)
W/L: 4095.00/2048.00

P/A

↑ 04/08/2013

04/08/2013

3/3

Image: 3
YPos: PA
Q: 1993

100 mm

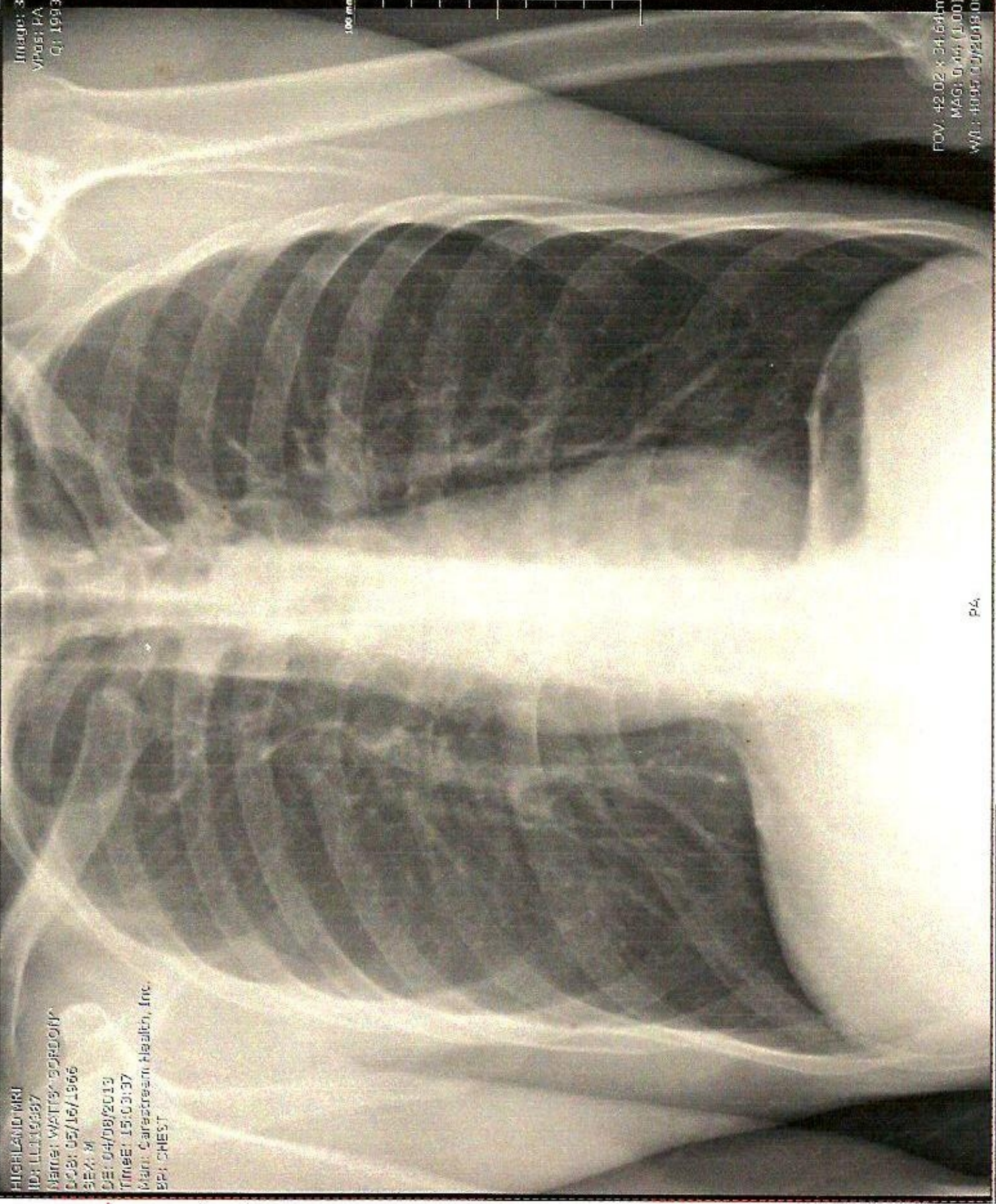
FOV: 42.02 x 34.54 cm
MAG: 0.44 (1.00)
WI: 4095.00/2048.00

HIGHLAND MRI
ID: LL19987
Name: WATTS, BORDON
DOB: 05/15/1966
SEX: M
DE: 04/08/2013
TIME: 15:03:37
Man: Carestream Health, Inc.
BY: CHEST

↑ (04/05/2013)

P4

Prev Series Next Series



Patient Name: Watts, Gordon W
 Date of Birth: 05/16/1966
 Telephone: 863-688-9880

Pedro Ruiz MD
 4740 Exploration Ave
 FL-33812
 863-666-9020

(06/20/2013 04/05/2013)

Hemoglobin A1c		
COLLECTION DATE	06/20/2013	04/05/2013
ORDER DATE	06/20/2013	04/05/2013
RESULT DATE	06/21/2013	04/09/2013
ORDERING PHYSICIAN	Pedro Ruiz	Michael L Strickland
Hemoglobin A1c	5.4 (4.8-5.6 %)	5.2 (4.8-5.6 %)

CBC with Differential/Platelet		
COLLECTION DATE	06/20/2013	04/05/2013
ORDER DATE	06/20/2013	04/05/2013
RESULT DATE	06/21/2013	04/09/2013
ORDERING PHYSICIAN	Pedro Ruiz	Michael L Strickland
WBC	5.3 (4.0-10.5 x10E3/uL)	6.3 (4.0-10.5 x10E3/uL)
RBC	3.90 (4.14-5.80 x10E6/uL) L	3.97 (4.14-5.80 x10E6/uL) L
HEMOGLOBIN	11.2 (12.6-17.7 g/dL) L	12.4 (12.6-17.7 g/dL) L
HEMATOCRIT	36.0 (37.5-51.0 %) L	37.5 (37.5-51.0 %)
MCV	92 (79-97 fL)	95 (79-97 fL)
MCH	28.7 (26.6-33.0 pg)	31.2 (26.6-33.0 pg)
MCHC	31.1 (31.5-35.7 g/dL) L	33.1 (31.5-35.7 g/dL)
RDW	12.9 (12.3-15.4 %)	13.6 (12.3-15.4 %)
PLATELET COUNT	337 (140-415 x10E3/uL)	290 (140-415 x10E3/uL)
ABSOLUTE NEUTROPHILS	3.3 (1.8-7.8 x10E3/uL)	4.5 (1.8-7.8 x10E3/uL)
NEUTROPHILS %	62 (40-74 %)	72 (40-74 %)
ABSOLUTE LYMPHOCYTES	1.1 (0.7-4.5 x10E3/uL)	1.0 (0.7-4.5 x10E3/uL)
LYMPHOCYTES %	21 (14-46 %)	15 (14-46 %)
ABSOLUTE MONOCYTES	0.3 (0.1-1.0 x10E3/uL)	0.4 (0.1-1.0 x10E3/uL)
MONOCYTES %	6 (4-13 %)	6 (4-13 %)
ABSOLUTE EOSINOPHILS	0.5 (0.0-0.4 x10E3/uL) H	0.4 (0.0-0.4 x10E3/uL)
EOSINOPHILS %	10 (0-7 %) H	6 (0-7 %)
ABSOLUTE BASOPHILS	0.1 (0.0-0.2 x10E3/uL)	0.0 (0.0-0.2 x10E3/uL)
BASOPHILS %	1 (0-3 %)	1 (0-3 %)

Ferritin		

COLLECTION DATE	06/20/2013	04/05/2013
ORDER DATE	06/20/2013	04/05/2013
RESULT DATE	06/21/2013	04/09/2013
ORDERING PHYSICIAN	Pedro Ruiz	Michael L Strickland
FERRITIN	22 (30-400 ng/mL) L	44 (30-400 ng/mL)

Folate (Folic Acid), Serum	
COLLECTION DATE	04/05/2013
ORDER DATE	04/05/2013
RESULT DATE	04/09/2013
ORDERING PHYSICIAN	Michael L Strickland
Folate (Folic Acid), Serum	17.7 (>3.0 ng/mL)

VITAMIN B12	
COLLECTION DATE	04/05/2013
ORDER DATE	04/05/2013
RESULT DATE	04/09/2013
ORDERING PHYSICIAN	Michael L Strickland
VITAMIN B12	>1999 (211-946 pg/mL) H

Lipid Panel	
COLLECTION DATE	04/05/2013
ORDER DATE	04/05/2013
RESULT DATE	04/09/2013
ORDERING PHYSICIAN	Michael L Strickland
Cholesterol, Total	137 (100-199 mg/dL)
Triglycerides	49 (0-149 mg/dL)
HDL Cholesterol	55 (>39 mg/dL)
LDL Cholesterol Calc	72 (0-99 mg/dL)
VLDL Cholesterol Cal	10 (5-40 mg/dL)

PSA	
COLLECTION DATE	04/05/2013
ORDER DATE	04/05/2013
RESULT DATE	04/09/2013
ORDERING PHYSICIAN	Michael L Strickland
PSA, Total	2.9 (0.0-4.0 ng/mL)

Patient: Watts, Gordon W DOB: 05/16/1966

6/20/2013

Basic Metabolic Panel W/ GFR Ratio	
COLLECTION DATE	04/05/2013
ORDER DATE	04/05/2013
RESULT DATE	04/09/2013
ORDERING PHYSICIAN	Michael L Strickland
GLUCOSE	110 (65-99 mg/dL) H
BUN	16 (6-24 mg/dL)
CREATININE	0.95 (0.76-1.27 mg/dL)
BUN/CREATININE RATIO	17 (9-20)
GFR AFRICAN AMERICAN	111 (>59 mL/min/1.73)
GFR NON-AFRICAN AMER	96 (>59 mL/min/1.73)
SODIUM	140 (134-144 mmol/L)
POTASSIUM	4.0 (3.5-5.2 mmol/L)
CHLORIDE	107 (97-108 mmol/L)
CARBON DIOXIDE	25 (20-32 mmol/L)
CALCIUM	8.7 (8.7-10.2 mg/dL)

Liver Function Tests - LFTs	
COLLECTION DATE	04/05/2013
ORDER DATE	04/05/2013
RESULT DATE	04/09/2013
ORDERING PHYSICIAN	Michael L Strickland
Total Protein	6.1 (6.0-8.5 g/dL)
Albumin	4.1 (3.5-5.5 g/dL)
BILIRUBIN TOTAL	0.2 (0.0-1.2 mg/dL)
BILIRUBIN DIRECT	0.10 (0.00-0.40 mg/dL)
ALKALINE PHOSPHATASE	56 (25-150 IU/L)
AST (SGOT)	18 (0-40 IU/L)
ALT (SGPT)	13 (0-44 IU/L)

TSH	
COLLECTION DATE	04/05/2013
ORDER DATE	04/05/2013
RESULT DATE	04/09/2013
ORDERING PHYSICIAN	Michael L Strickland
TSH	2.280 (0.450-4.500 uIU/mL)

FACSIMILE TRANSMITTAL FORM

Date/Time: 7/15/2013 2:54:43 PM

Pages: 4

Subject: Cumulative eReport

To:

Fax Number: 863-614-1702

From: Willis, Susan L

Fax Number: 863-606-0887

Business Phone: 863-666-9020

Company: PEDRO RUIZ MD PA

**NOTE: PLEASE CALL 863-666-9020 IF DOCUMENTS ARE INCOMPLETE
OR NOT LEGIBLE.**

The information contained in the facsimile message may be confidential and/or legally privileged information intended only for the use of the individual or entity named above. If the reader of this message is not the intended recipient, you are hereby notified that any copying, dissemination, or distribution of confidential or privileged information is strictly prohibited.

If you have received this communication in error, please notify us immediately by telephone and we will arrange for return of the documents.

BARTOW REGIONAL MEDICAL CENTER
BARTOW, FL 33830
OPERATIVE REPORT

PATIENT: WATTS, GORDON RM #:
DOB: 05/16/1966 ACCOUNT #: 3411044
ATTENDING: Saeed Ahmed, MD MR #: 000396745
DICTATING: Saeed Ahmed, MD DATE PERFORMED: 07/22/2013

DATE OF OPERATION: 07/22/2013

07/22/2013

PRIMARY CARE PHYSICIAN: Pedro Ruiz, MD

SCANNED

SURGEON: Saeed Ahmed, MD

TYPE OF PROCEDURE: ~~Colonoscopy~~ EGD

INDICATION FOR THE PROCEDURE: Iron-deficiency anemia.

CONSENT: An informed consent was obtained after explaining the procedure, side effects, complications, and alternatives of the procedure.

PROCEDURE: After informed consent, the patient was placed in the left lateral position. Sedation was given using MAC anesthesia. Once sedated, Olympus GIF-160AL gastroscope was inserted into the oropharynx and then advanced under direct visualization into the esophagus, stomach, and up to the second part of the duodenum. The scope was then pulled back evaluating the mucosal lining. In the stomach, retroflexion was performed. The patient tolerated the procedure well. There were no immediate complications.

FINDINGS:

1. Esophagus: The esophagus appears normal without evidence of ulcerations, erosions, edema, or erythema. Squamocolumnar junction was located at 40 cm from the incisors and it was normal.
2. Stomach: There was evidence of edema, erythema and a few erosions in the antrum. Biopsies were obtained and sent for surgical pathology. The body, fundus, and cardia appears normal.
3. Duodenum: There was evidence of duodenitis with erosions, edema, erythema in the bulb. The second and third part of the duodenum appear normal. I took random biopsies of the second and third part, as well as from the duodenal bulb for workup for his anemia and sent for surgical pathology.

IMPRESSION:

1. Normal esophagus.
2. Erosive antral gastropathy, biopsies obtained.
3. Duodenitis in the bulb. Biopsies obtained.

BARTOW REGIONAL MEDICAL CENTER
BARTOW, FL 33830
OPERATIVE REPORT

PATIENT: WATTS, GORDON
DOB: 05/16/1966
ATTENDING: Saeed Ahmed, MD
DICTATING: Saeed Ahmed, MD

RM #:
ACCOUNT #: 3411044
MR #: 000396745
DATE PERFORMED: 07/22/2013

RECOMMENDATIONS: Follow up biopsy results. Avoid NSAIDs. Treat for H. pylori if positive. Proceed with colonoscopy.

Dr. Ruiz, thank you very much for referring this gentleman, and allowing me to participate in his care.

Saeed Ahmed, MD

Date: _____ Time: _____

DD: Mon Jul 22 11:22:17 2013
DT: Mon Jul 22 13:57:04 2013
JOB: 78517057
3414 /88017
CC: Pedro Ruiz, MD

DICTATED/TRANSCRIBED

BARTOW REGIONAL MEDICAL CENTER
BARTOW, FL 33830
OPERATIVE REPORT

COPIED

PATIENT: WATTS, GORDON
DOB: 05/16/1966
ATTENDING: Saeed Ahmed, MD
DICTATING: Saeed Ahmed, MD

RM #:
ACCOUNT #: 3411044
MR #: 000396745
DATE PERFORMED: 07/22/2013

DATE OF OPERATION: 07/22/2013

SURGEON: Saeed Ahmed, MD

TYPE OF PROCEDURE: Colonoscopy.

PRIMARY CARE PHYSICIAN: Dr. Ruiz



INDICATION FOR THE PROCEDURE: Microcytic anemia, iron-deficiency anemia.

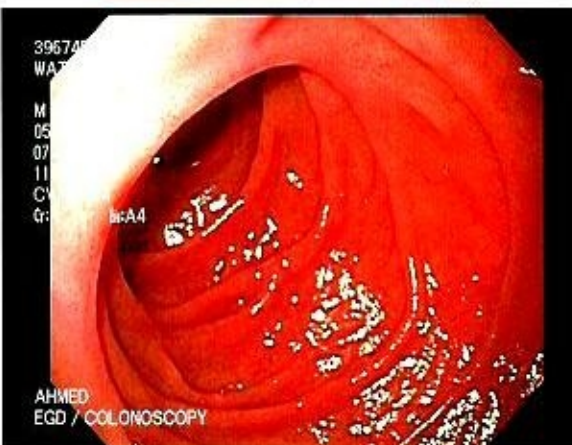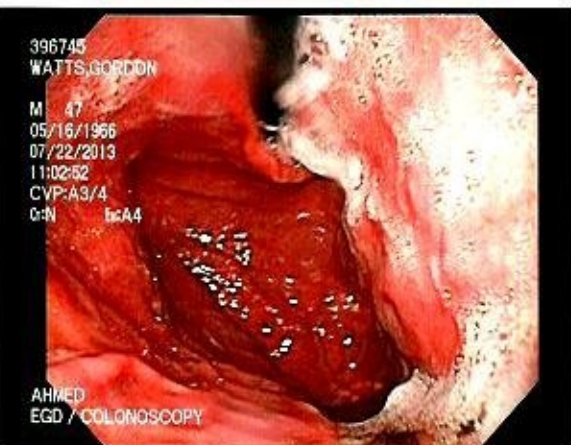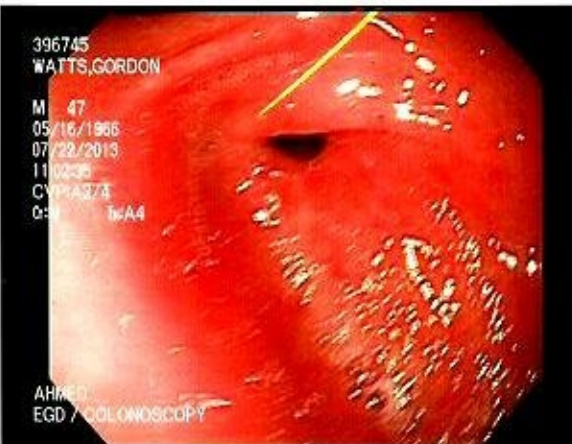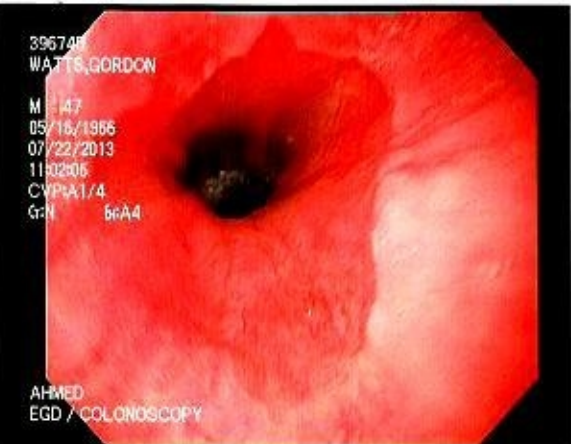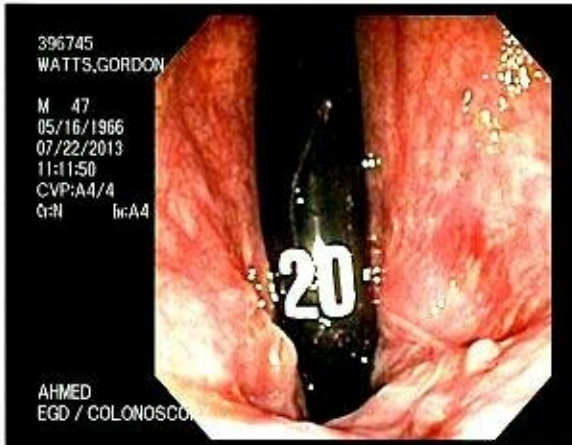
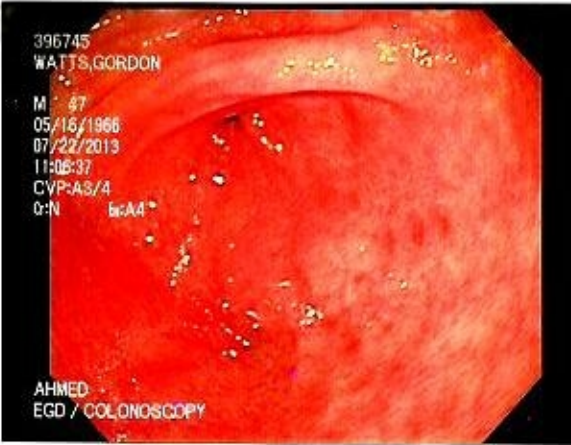
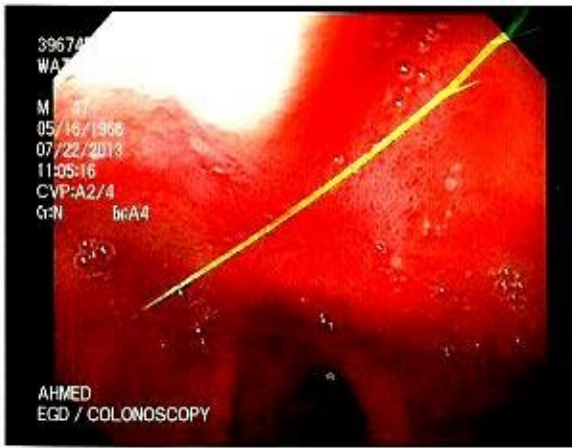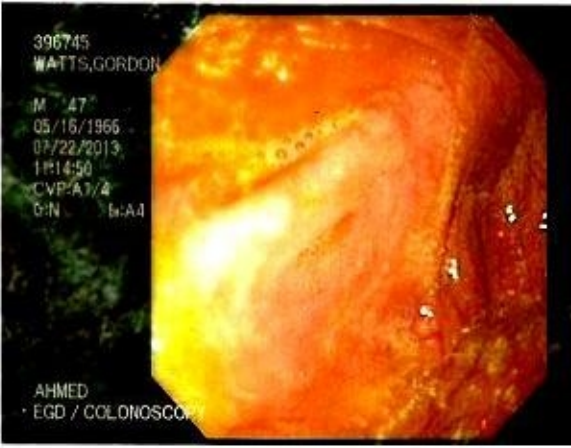CONSENT: An informed consent was obtained after explaining the procedure, side effects, complications, and alternatives of the procedure.

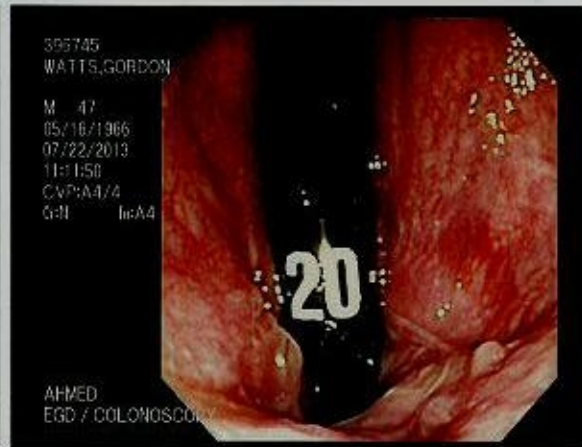
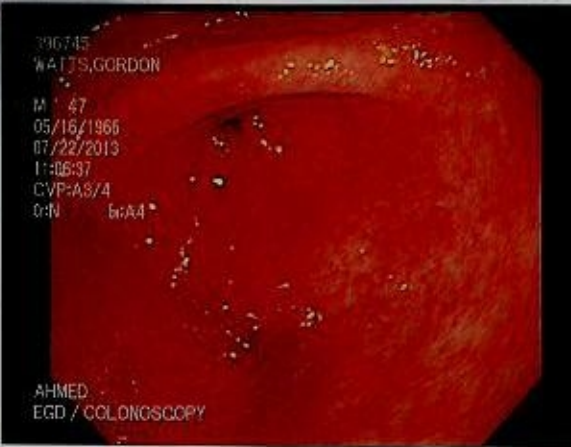
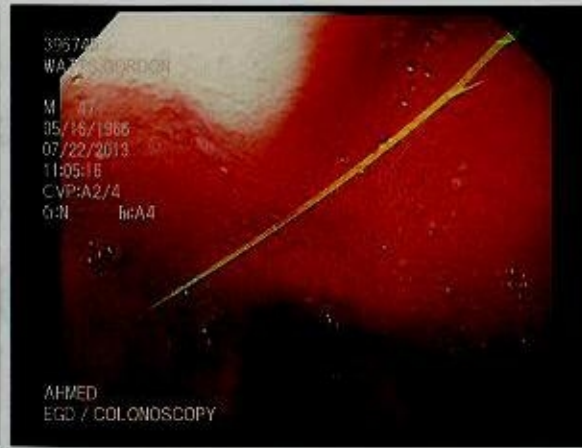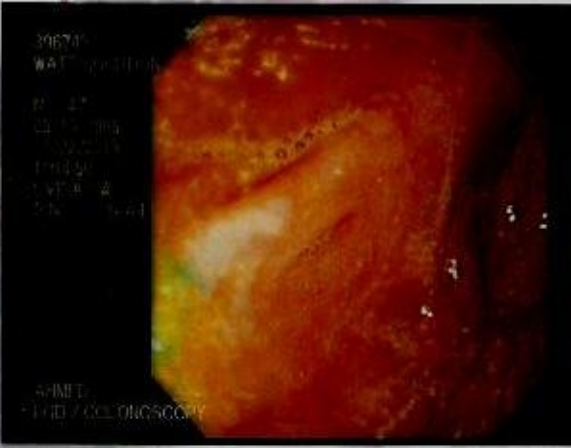
PROCEDURE: After an informed consent, the patient was placed in the left lateral position. Sedation was given using MAC anesthesia. Once sedated, an EGD was performed. Please review separate EGD report for details. After the EGD, an Olympus PCF-160AL colonoscope was inserted into the rectum, then advanced under direct visualization up to the cecum, which was identified by the ileocecal valve and appendiceal orifice. The scope was then pulled back evaluating the mucosal lining. In the rectum retroflexion was performed. The patient tolerated the procedure well. There were no immediate complications.

FINDINGS: There were internal hemorrhoids noted on retroflexion at the anorectal junction. Digital rectal examination was normal. Other than these findings the rest of the colon appears normal up to cecum. No polyps, angiodysplasias, diverticula or colitis identified.

IMPRESSION: Normal colonoscopy up to the cecum.

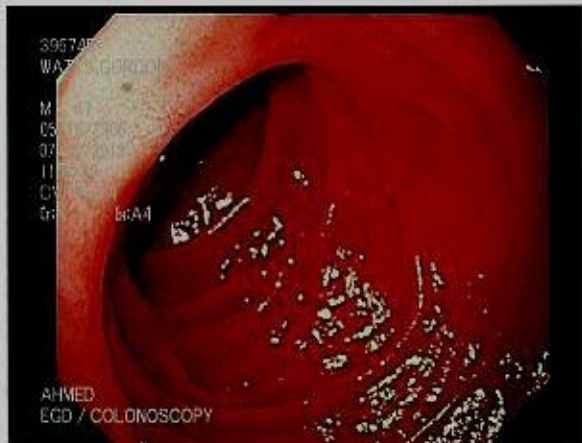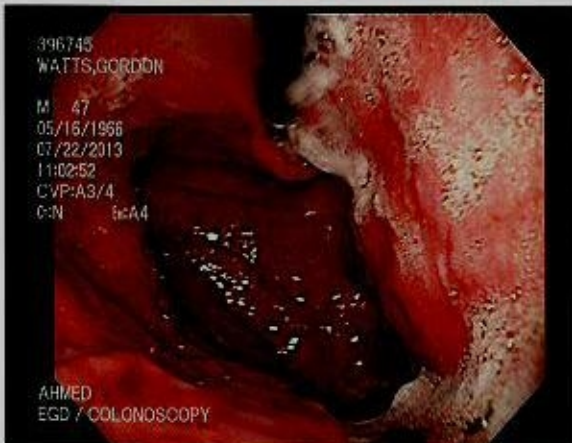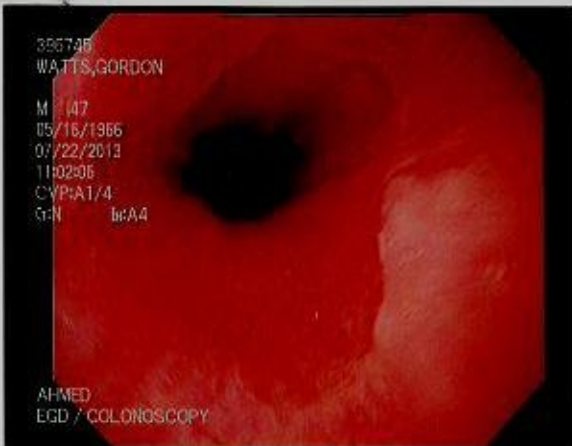
RECOMMENDATIONS: Follow up in the office in 1 to 2 weeks for followup of his EGD findings. If anemia persists, we may consider a capsule endoscopy.





07/22/2013

SCANNED



07/22/2013

SCANNED

GASTROINTESTINAL PATHOLOGY REPORT

PATIENT: WATTS, GORDON
Date of Birth: 5/16/1966 Age: 47 Sex: M
Social Security #: 595-09-7835
Location: Bartow Regional Medical Center
Submitting Physician: SAEED AHMED, MD
Copies To:

ACCESSION #: MPS-13-08493
ID #: 396745
Referring Lab #:
Date Received: 7/22/2013
Date of Procedure: 7/22/2013

07/22/2013

DIAGNOSIS:

- A) Duodenum, biopsy: Unremarkable intestinal mucosa.
 - B) Duodenal bulb, biopsy: Chronic active duodenitis with focal gastric (foveolar) metaplasia consistent with peptic ulcer disease.
 - C) Antrum of stomach, biopsy: Mild chronic gastritis.
- Immunohistochemical stain for Helicobacter pylori: Negative.** Control stain: Adequate.

SPECIMEN SOURCE:

- A. Duodenum
- B. Duodenal bulb
- C. Antrum of stomach

CLINICAL HISTORY:

Specimen A: Biopsy.
Specimen B: Biopsy.
Specimen C: Biopsy.

MACROSCOPIC DESCRIPTION:

- A) The multiple pieces of tan tissue measure 7 x 6 x 2 mm in aggregate. Some of the tissue fragments are miniscule and may not survive processing.
- B) The two pieces of tan tissue measure 7 x 4 x 2 mm in aggregate.
- C) The two pieces of tan tissue measure 7 x 5 x 2 mm in aggregate. CV/kd

Final Diagnosis performed by
EDWARD GARCIA, M.D.
Electronically signed 7/23/2013

SCANNED
ARCIA B.

BARTOW REGIONAL MEDICAL CENTER
BARTOW, FL 33830
OPERATIVE REPORT

PATIENT: WATTS, GORDON RM #:
DOB: 05/16/1966 ACCOUNT #: 3411044
ATTENDING: Saeed Ahmed, MD MR #: 000396745
DICTATING: Saeed Ahmed, MD DATE PERFORMED: 07/22/2013

Dr. Ruiz, thank you very much for referring this pleasant man and allowing me to participate in his care.

Saeed Ahmed, MD Date: _____ Time: _____

DD: Mon Jul 22 11:33:22 2013
DT: Mon Jul 22 14:05:38 2013
JOB: 78517458
3414 /88017
CC: Pedro Ruiz, MD

Dictated/Transcribed

Digestive Disease Assoc of Central FL-Lakeland

4712 Exploration Ave
 Lakeland, FL-338123319
 Tel: 863-614-1701 Fax: 863-614-1702

RECEIPT OF PAYMENT

Date: 08/06/2013

Received From: Watts, Gordon


Amount: 5.00 **Payment Type:** Cash **Payment Id:** 5322

Charges Detail

Date	Code Description	Units	Fee	Payment
08/06/2013	Patient Payment			5.00
Totals			0.00	5.00

Account Balance Summary

Total Balance: 1066.00
 Patient Balance: 0.00
 Insurance Balance: 1066.00



APPOINTMENT CARD

Patient Name: Watts, Gordon

Page 1 of 2

Patient Name: Watts, Gordon W
 Date of Birth: 05/16/1966
 Telephone: 863-688-9880

10/25/2013

Pedro Ruiz MD
 4740 Exploration Ave
 FL-33812
 863-666-9020

CBC with Differential/Platelet	
COLLECTION DATE	10/25/2013
ORDER DATE	10/24/2013
RESULT DATE	10/26/2013
ORDERING PHYSICIAN	Michael L Strickland
WBC	4.5 (3.4-10.8 x10E3/uL)
RBC	4.63 (4.14-5.80 x10E6/uL)
HEMOGLOBIN	14.1 (12.6-17.7 g/dL)
HEMATOCRIT	43.4 (37.5-51.0 %)
MCV	94 (79-97 fL)
MCH	30.5 (26.6-33.0 pg)
MCHC	32.5 (31.5-35.7 g/dL)
RDW	14.2 (12.3-15.4 %)
PLATELET COUNT	239 (155-379 x10E3/uL)
ABSOLUTE NEUTROPHILS	2.1 (1.4-7.0 x10E3/uL)
NEUTROPHILS %	46 (40-74 %)
ABSOLUTE LYMPHOCYTES	1.5 (0.7-3.1 x10E3/uL)
LYMPHOCYTES %	32 (14-46 %)
ABSOLUTE MONOCYTES	0.4 (0.1-0.9 x10E3/uL)
MONOCYTES %	9 (4-12 %)
ABSOLUTE EOSINOPHILS	0.5 (0.0-0.4 x10E3/uL) H
EOSINOPHILS %	11 (0-5 %) H
ABSOLUTE BASOPHILS	0.1 (0.0-0.2 x10E3/uL)
BASOPHILS %	2 (0-3 %)

VITAMIN B12	
COLLECTION DATE	10/25/2013
ORDER DATE	10/24/2013
RESULT DATE	10/26/2013
ORDERING PHYSICIAN	Michael L Strickland
VITAMIN B12	1821 (211-946 pg/mL) H

Lipid Panel	
COLLECTION DATE	10/25/2013
ORDER DATE	10/24/2013
RESULT DATE	10/26/2013
ORDERING PHYSICIAN	Michael L Strickland
Cholesterol, Total	138 (100-199 mg/dL)
Triglycerides	72 (0-149 mg/dL)
HDL Cholesterol	49 (>39 mg/dL)
LDL Cholesterol Calc	75 (0-99 mg/dL)
VLDL Cholesterol Cal	14 (5-40 mg/dL)

Patient: Watts, Gordon W DOB: 05/16/1966

10/25/2013

Page 2 of 2

Basic Metabolic Panel W/ GFR Ratio	
COLLECTION DATE	10/25/2013
ORDER DATE	10/24/2013
RESULT DATE	10/26/2013
ORDERING PHYSICIAN	Michael L Strickland
GLUCOSE	80 (65-99 mg/dL)
BUN	12 (6-24 mg/dL)
CREATININE	0.89 (0.76-1.27 mg/dL)
BUN/CREATININE RATIO	13 (9-20)
GFR AFRICAN AMERICAN	118 (>59 mL/min/1.73)
GFR NON-AFRICAN AMER	102 (>59 mL/min/1.73)
SODIUM	140 (134-144 mmol/L)
POTASSIUM	4.1 (3.5-5.2 mmol/L)
CHLORIDE	104 (97-108 mmol/L)
CARBON DIOXIDE	27 (19-28 mmol/L)
CALCIUM	9.0 (8.7-10.2 mg/dL)

Liver Function Tests - LFT's	
COLLECTION DATE	10/25/2013
ORDER DATE	10/24/2013
RESULT DATE	10/26/2013
ORDERING PHYSICIAN	Michael L Strickland
Total Protein	6.4 (6.0-8.5 g/dL)
Albumin	4.3 (3.5-5.5 g/dL)
BILIRUBIN TOTAL	0.4 (0.0-1.2 mg/dL)
BILIRUBIN DIRECT	0.10 (0.00-0.40 mg/dL)
ALKALINE PHOSPHATASE	52 (44-102 IU/L)
AST (SGOT)	18 (0-40 IU/L)
ALT (SGPT)	11 (0-44 IU/L)

TSH	
COLLECTION DATE	10/25/2013
ORDER DATE	10/24/2013
RESULT DATE	10/26/2013
ORDERING PHYSICIAN	Michael L Strickland
TSH	1.830 (0.450-4.500 uIU/mL)

Hemoglobin A1c	
COLLECTION DATE	10/25/2013
ORDER DATE	10/24/2013
RESULT DATE	10/26/2013
ORDERING PHYSICIAN	Michael L Strickland
Hemoglobin A1c	5.8 (4.8-5.6 %) H

6.0-6.5
Diet
6.5-7 Modest

Patient: Watts, Gordon W DOB: 05/16/1966